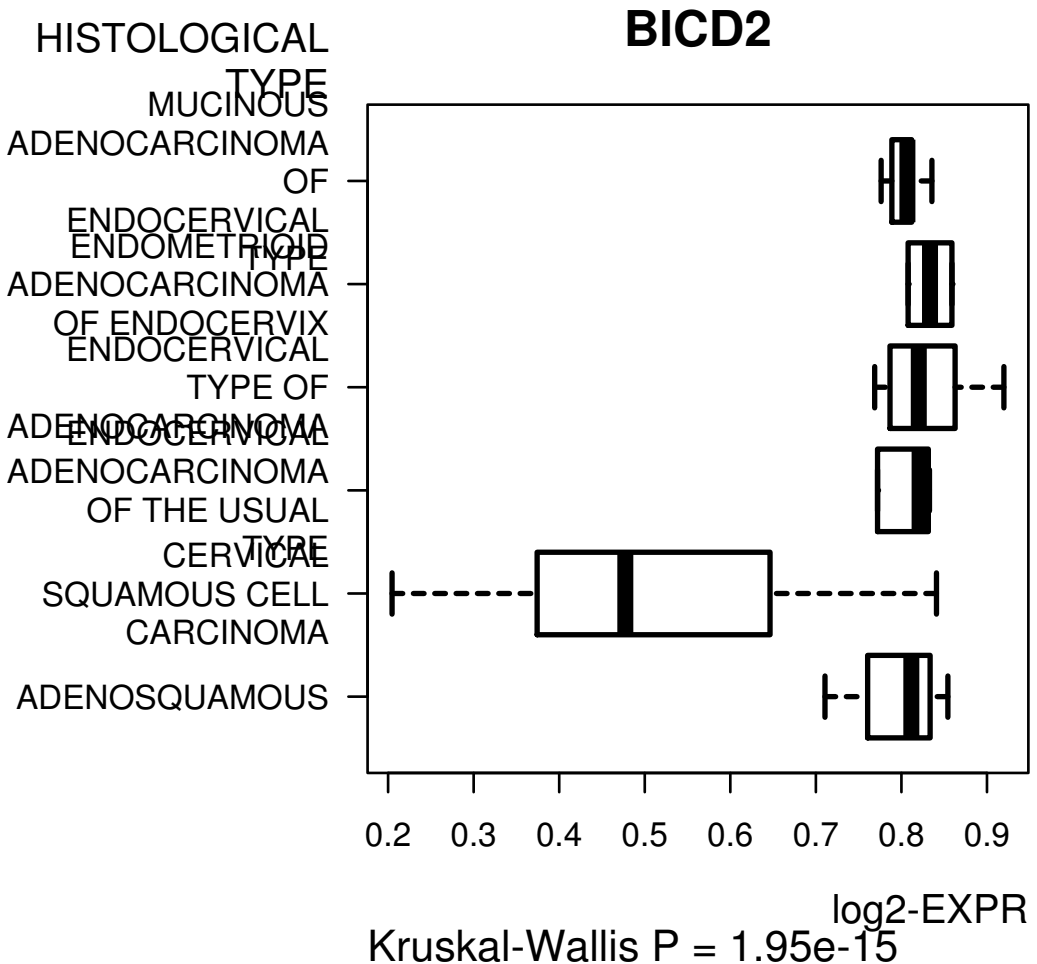
BICD2
HISTOLOGICAL TYPE
MUCINOUS ADENOCARCINOMA OF ENDOCERVICAL TYPE
ENDOMETRIOID ADENOCARCINOMA OF ENDOCERVIX
ENDOCERVICAL TYPE OF ADENOCARCINOMA
ENDOCERVICAL ADENOCARCINOMA OF THE USUAL TYPE
CERVICAL SQUAMOUS CELL CARCINOMA
ADENOSQUAMOUS
0.2
0.3
0.4
0.5
0.6
0.7
0.8
0.9
log2-EXPR
Kruskal-Wallis P = 1.95e-15