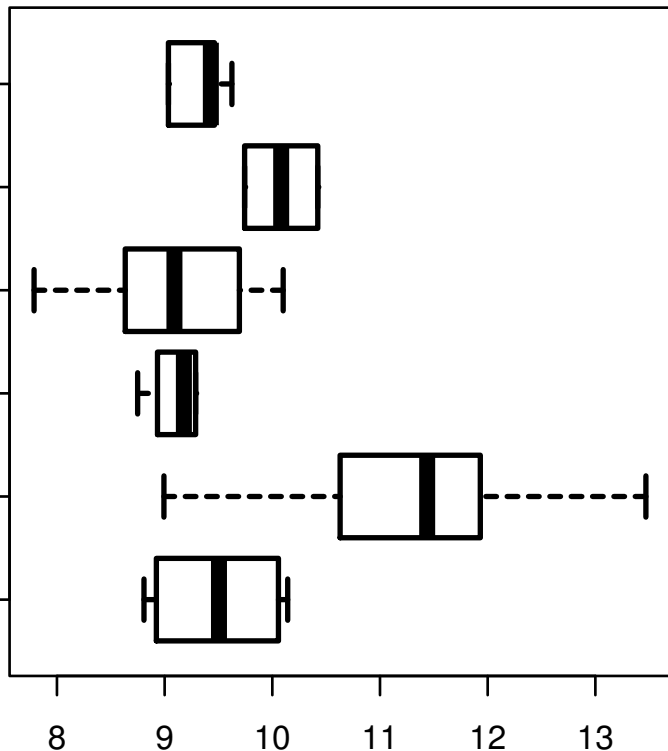


# BICD2|23299

HISTOLOGICAL  
TYPE  
MUCINOUS  
ADENOCARCINOMA  
OF  
ENDOCERVICAL  
ENDOMETRIUM  
TYPE  
ADENOCARCINOMA  
OF ENDOCERVIX  
ENDOCERVICAL  
TYPE OF  
ADENOCARCINOMA  
ENDOCERVICAL  
ADENOCARCINOMA  
OF THE USUAL  
CERVICAL  
TYPE  
SQUAMOUS CELL  
CARCINOMA  
ADENOSQUAMOUS



log2-EXPR  
Kruskal-Wallis P = 7.96e-17