

GPR109B|8843

HISTOLOGICAL

TYPE

MUCINOUS

ADENOCARCINOMA

OF

ENDOCERVICAL

ENDOMETRIUM

ADENOCARCINOMA

OF ENDOCERVIX

ENDOCERVICAL

TYPE OF

ADENOCARCINOMA

ENDOCERVICAL

ADENOCARCINOMA

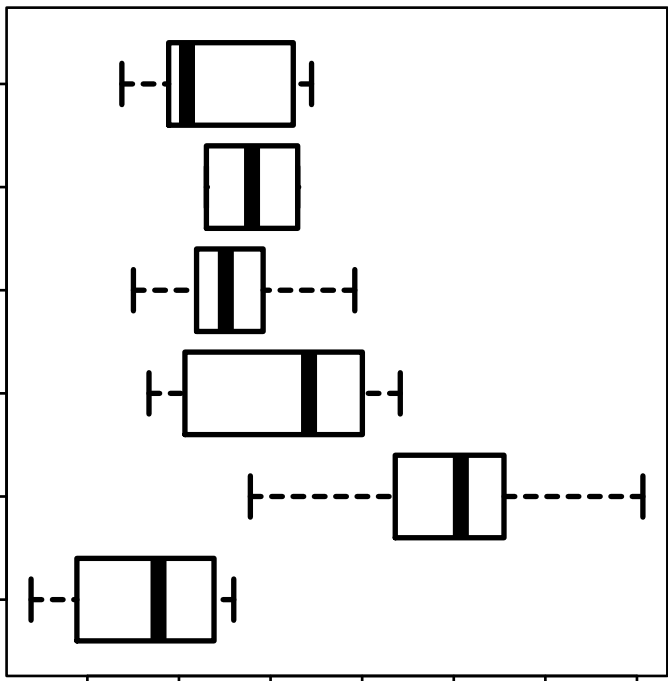
OF THE USUAL

CERVICAL

SQUAMOUS CELL

CARCINOMA

ADENOSQUAMOUS



log2-EXPR

Kruskal-Wallis P = 2.91e-16