

# HSA-MIR-944

HISTOLOGICAL  
TYPE

MUCINOUS  
ADENOCARCINOMA

OF

ENDOCERVICAL

ENDOMETRIUM

TYPE

ADENOCARCINOMA

OF ENDOCERVIX

ENDOCERVICAL

TYPE OF

ADENOCARCINOMA

ENDOCERVICAL

ADENOCARCINOMA

OF THE USUAL

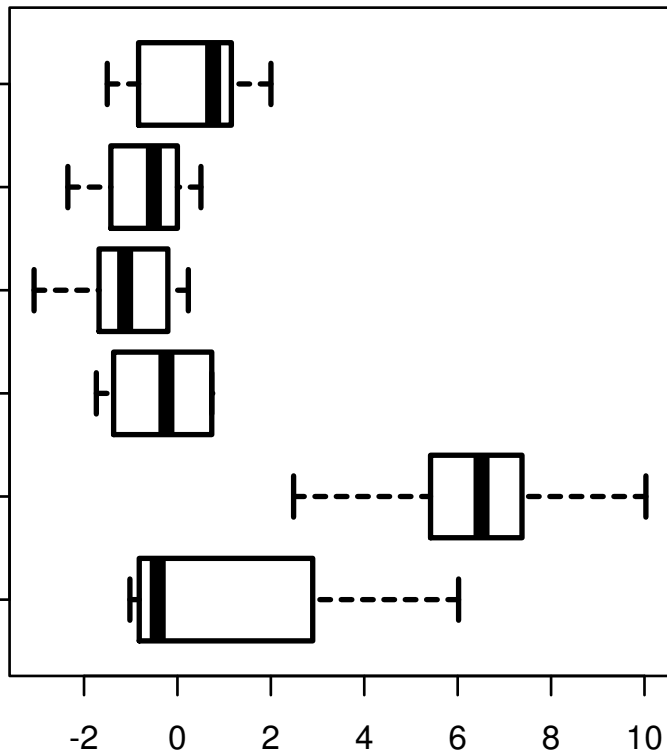
CERVICAL

TYPE

SQUAMOUS CELL

CARCINOMA

ADENOSQUAMOUS



log2-EXPR  
Kruskal-Wallis P = 1.4e-13