

# HSA-MIR-221

HISTOLOGICAL  
TYPE

MUCINOUS  
ADENOCARCINOMA  
OF

ENDOCERVICAL  
ENDOMETRIAL

ADENOCARCINOMA  
OF ENDOCERVIX

ENDOCERVICAL  
TYPE OF

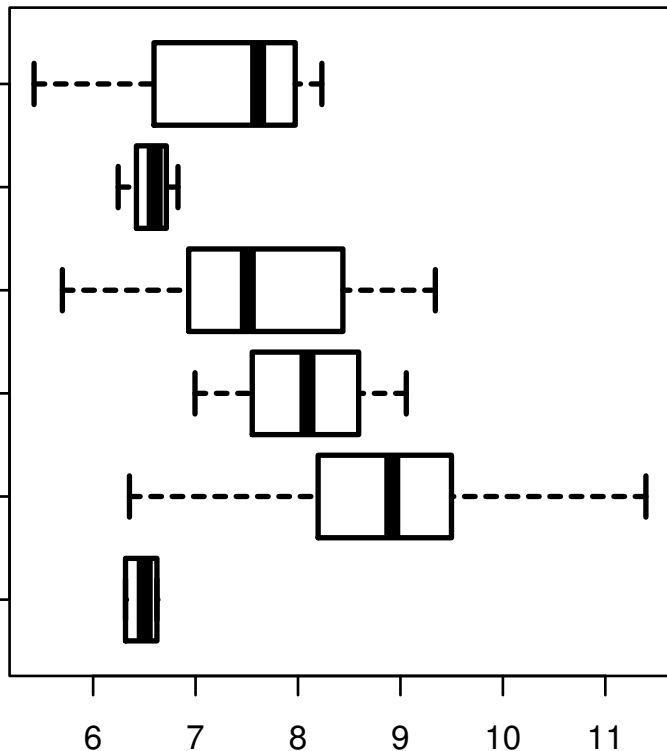
ADENOCARCINOMA  
ENDOCERVICAL

ADENOCARCINOMA  
OF THE USUAL

CERVICAL  
TYPE

SQUAMOUS CELL  
CARCINOMA

ADENOSQUAMOUS



log2-EXPR  
Kruskal-Wallis P = 1.02e-08