

PRAC

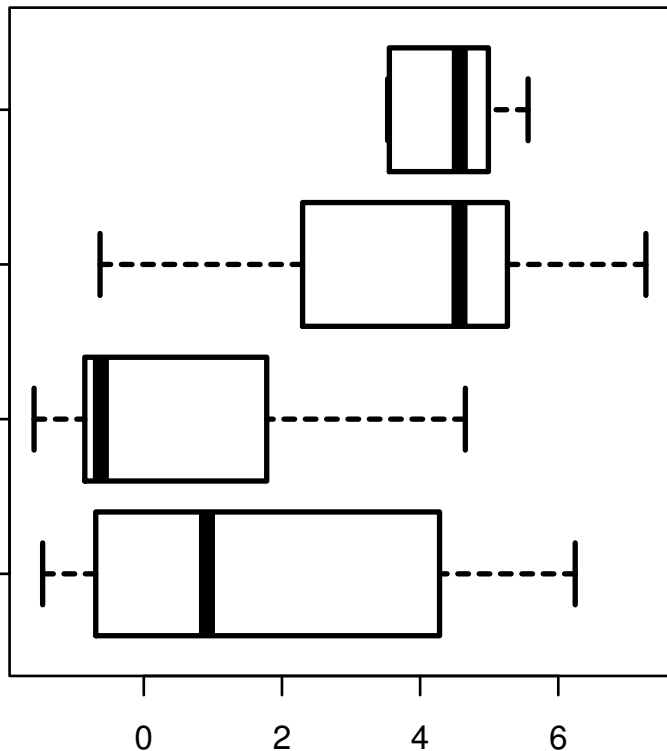
HISTOLOGICAL
TYPE

RECTAL
MUCINOUS
ADENOCARCINOMA

RECTAL
ADENOCARCINOMA

COLON
MUCINOUS
ADENOCARCINOMA

COLON
ADENOCARCINOMA



log2-EXPR
Kruskal-Wallis P = 4.17e-10