

C20ORF43__1

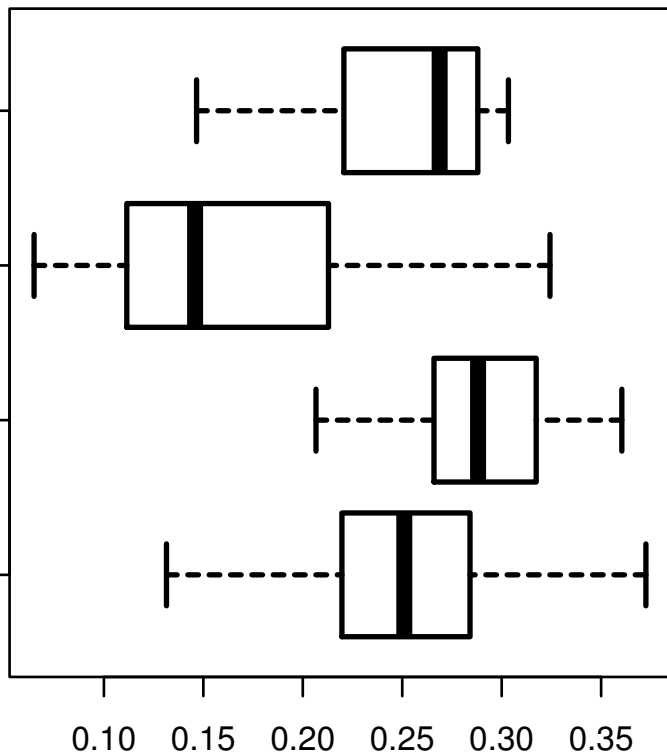
HISTOLOGICAL
TYPE

RECTAL
MUCINOUS
ADENOCARCINOMA

RECTAL
ADENOCARCINOMA

COLON
MUCINOUS
ADENOCARCINOMA

COLON
ADENOCARCINOMA



log2-EXPR

Kruskal-Wallis P = 2.15e-26