

# XIAP|XIAP-R-C

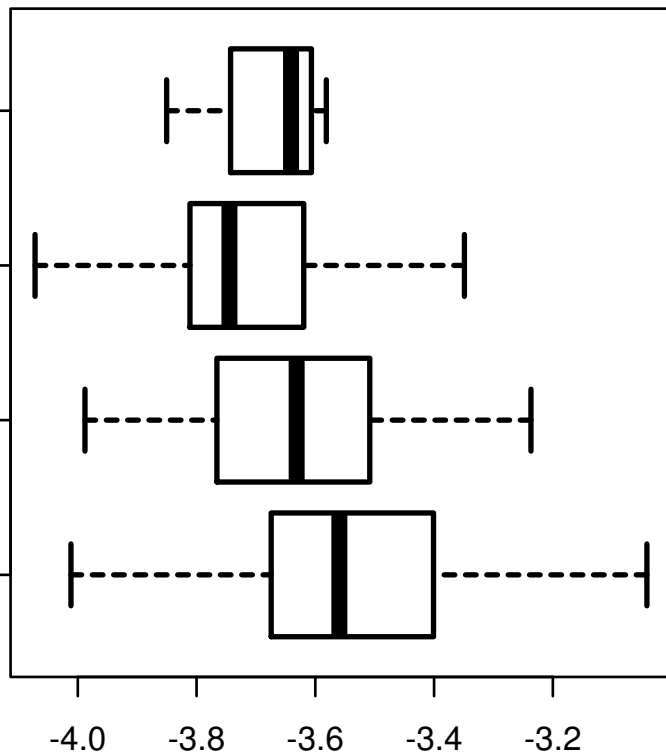
HISTOLOGICAL  
TYPE

RECTAL  
MUCINOUS  
ADENOCARCINOMA

RECTAL  
ADENOCARCINOMA

COLON  
MUCINOUS  
ADENOCARCINOMA

COLON  
ADENOCARCINOMA



log2-EXPR  
Kruskal-Wallis P = 1.98e-14