

SLC5A6|8884

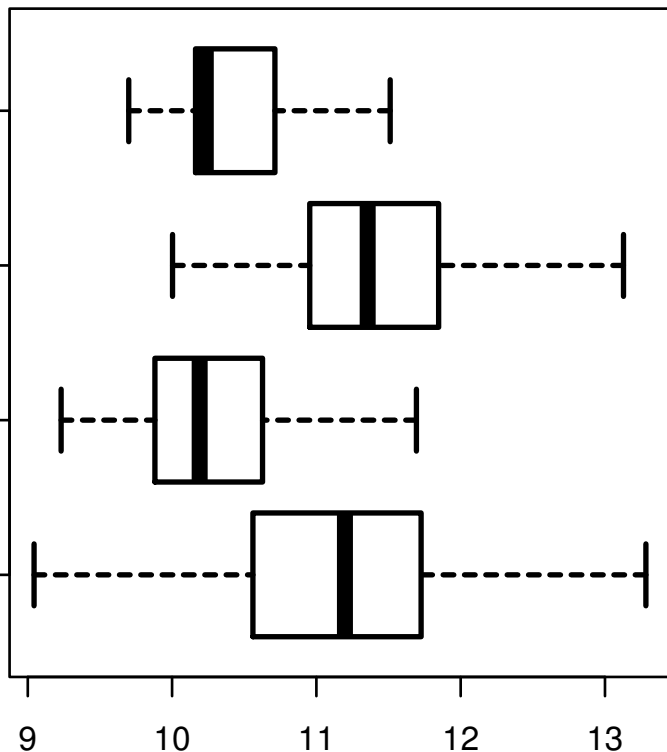
HISTOLOGICAL
TYPE

RECTAL
MUCINOUS
ADENOCARCINOMA

RECTAL
ADENOCARCINOMA

COLON
MUCINOUS
ADENOCARCINOMA

COLON
ADENOCARCINOMA



log2-EXPR

Kruskal-Wallis P = 3.37e-17