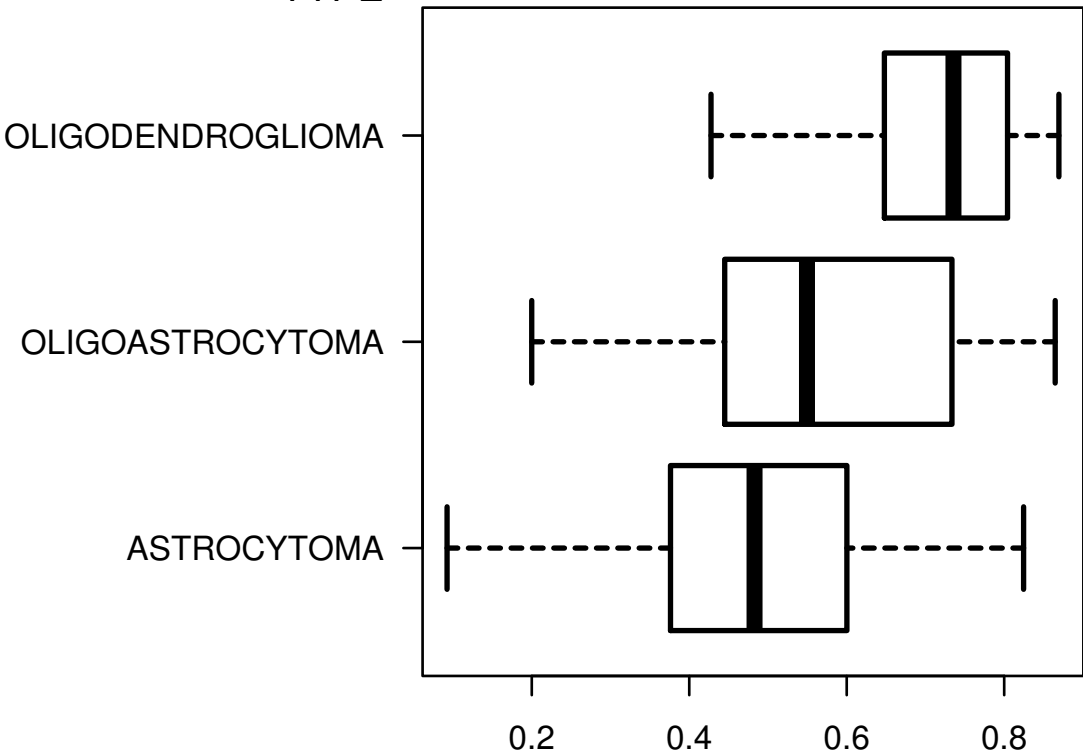


HISTOLOGICAL
TYPE

TMC6



log2-EXPR
Kruskal-Wallis P = 1.53e-25