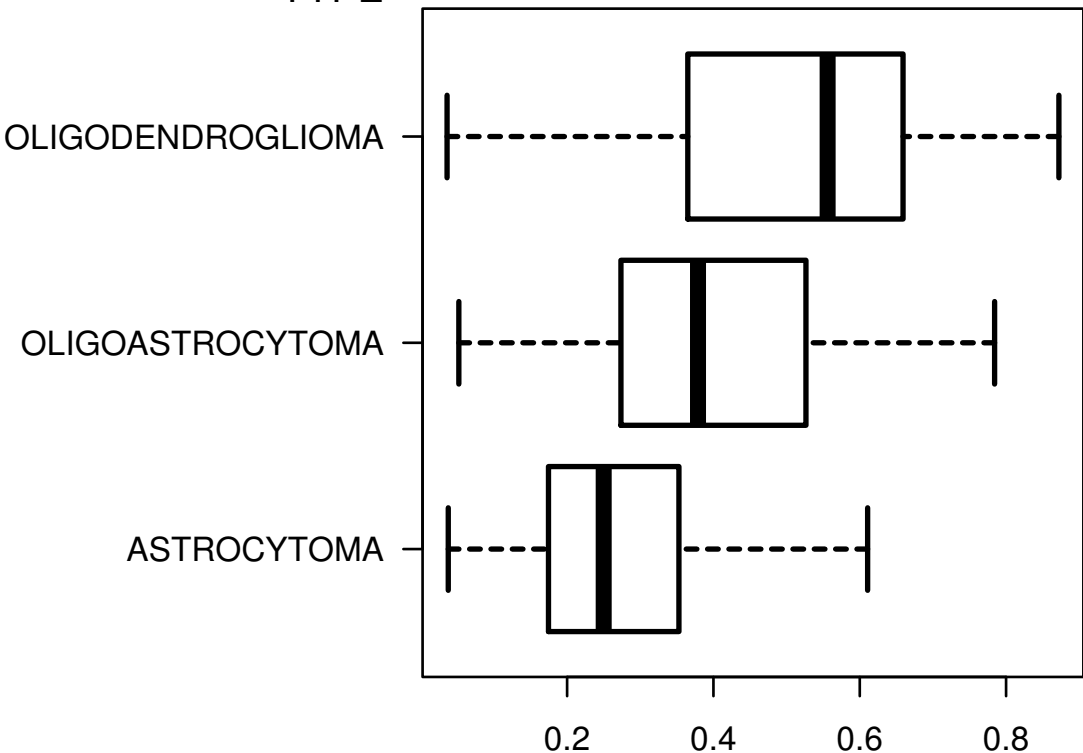


HISTOLOGICAL
TYPE

CBX2



log₂-EXPR
Kruskal-Wallis P = 2.97e-27