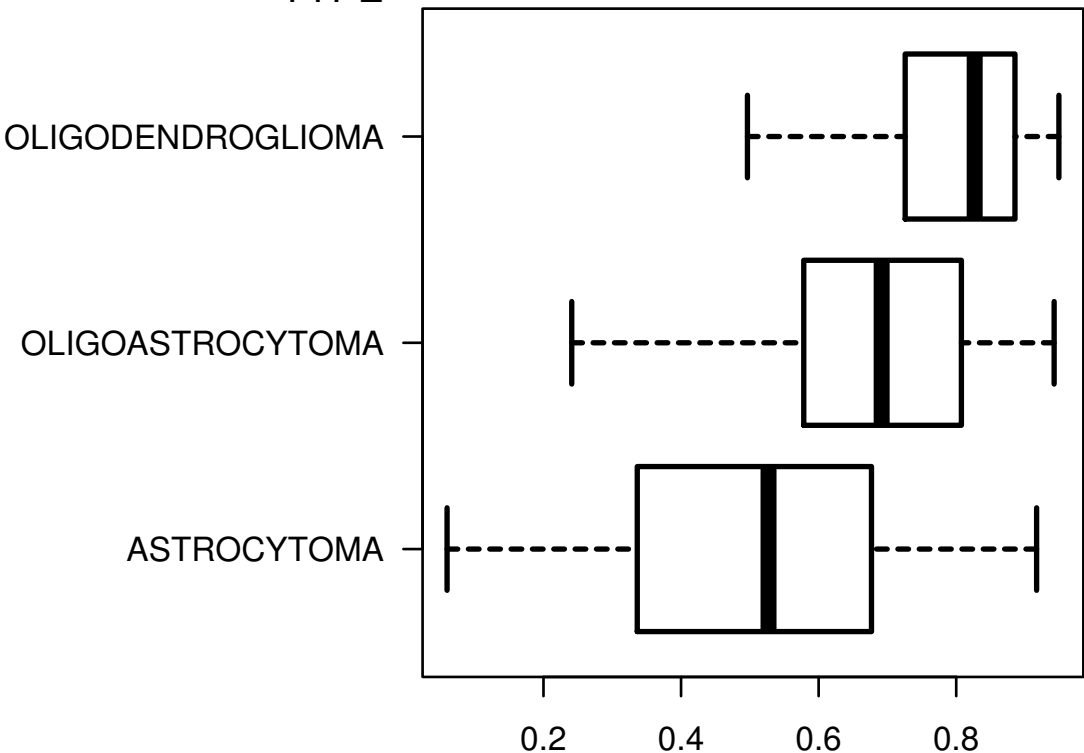


HISTOLOGICAL
TYPE

EMP1



log2-EXPR

Kruskal-Wallis P = 1.04e-26