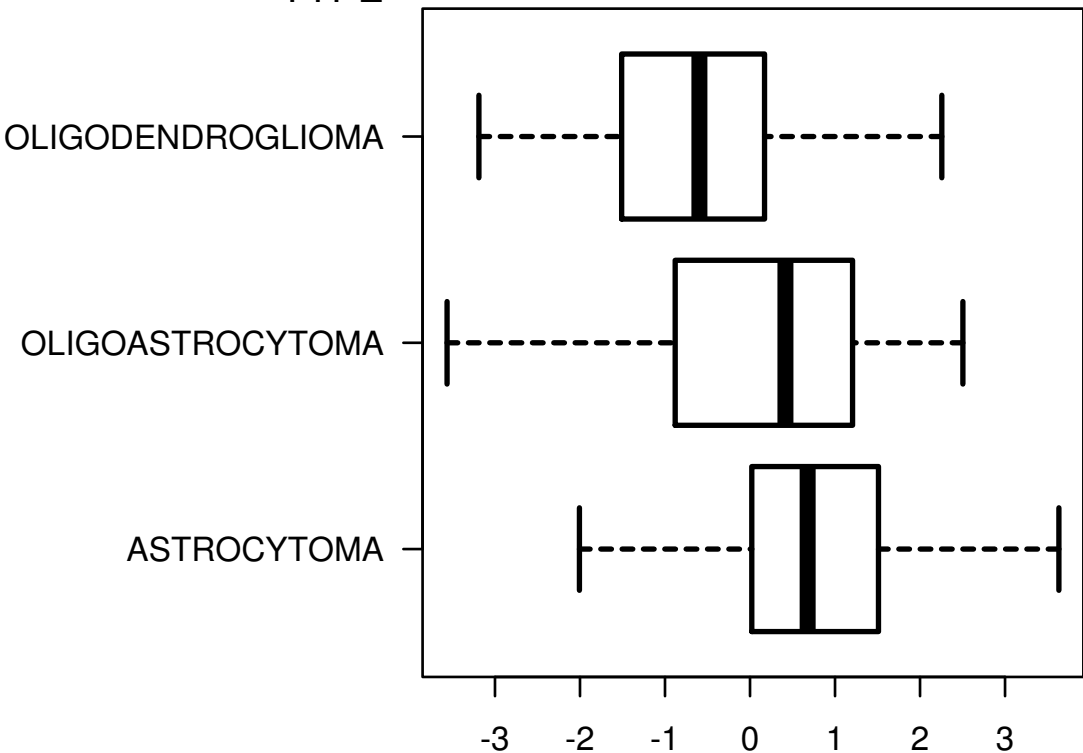


HSA-MIR-1262

HISTOLOGICAL
TYPE



Kruskal-Wallis P = 1.59e-17