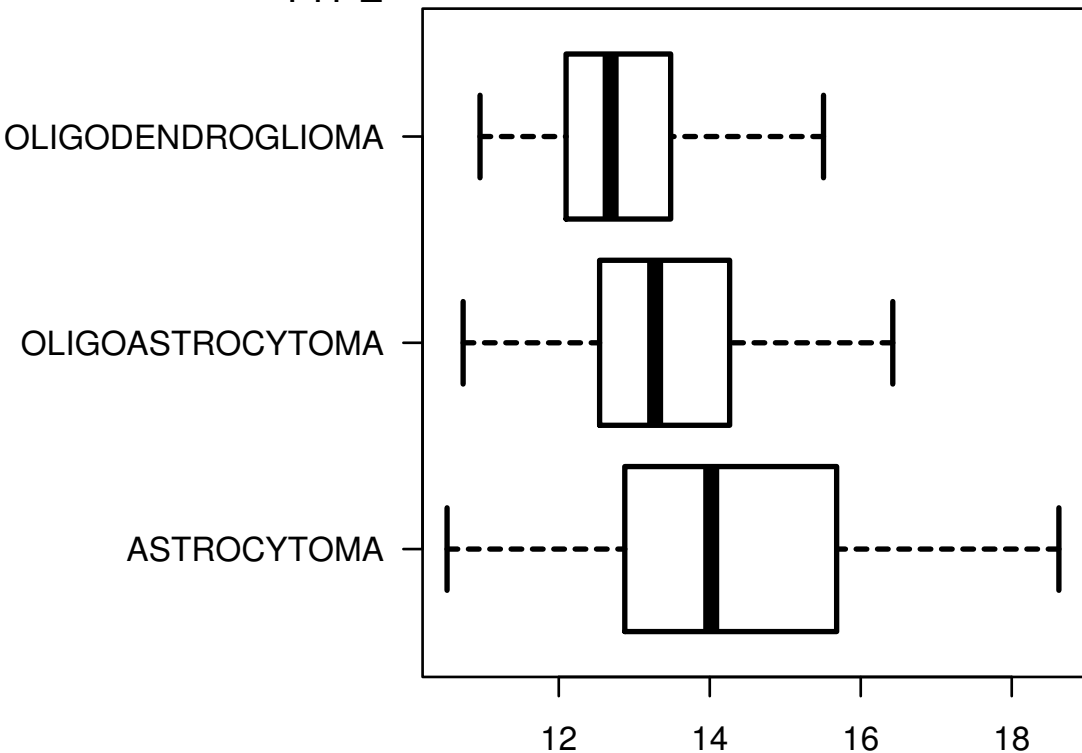


HSA-MIR-21

HISTOLOGICAL
TYPE



log2-EXPR
Kruskal-Wallis P = 3.64e-12