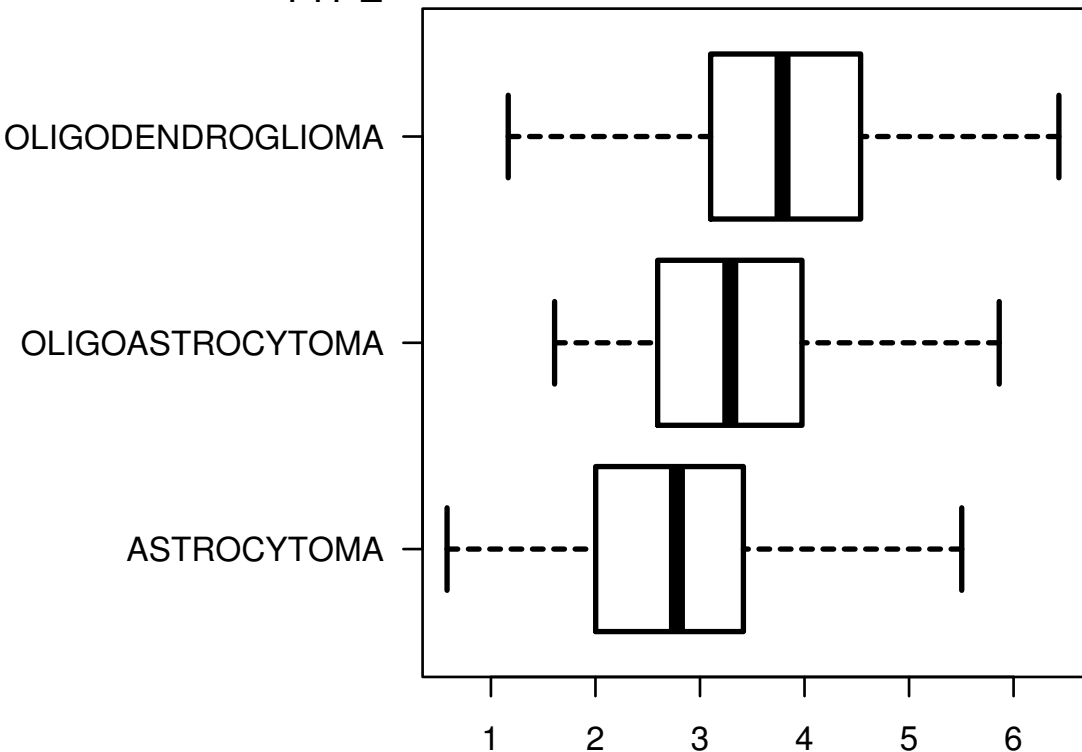


HSA-MIR-592

HISTOLOGICAL
TYPE



log₂-EXPR
Kruskal-Wallis P = 3.2e-15