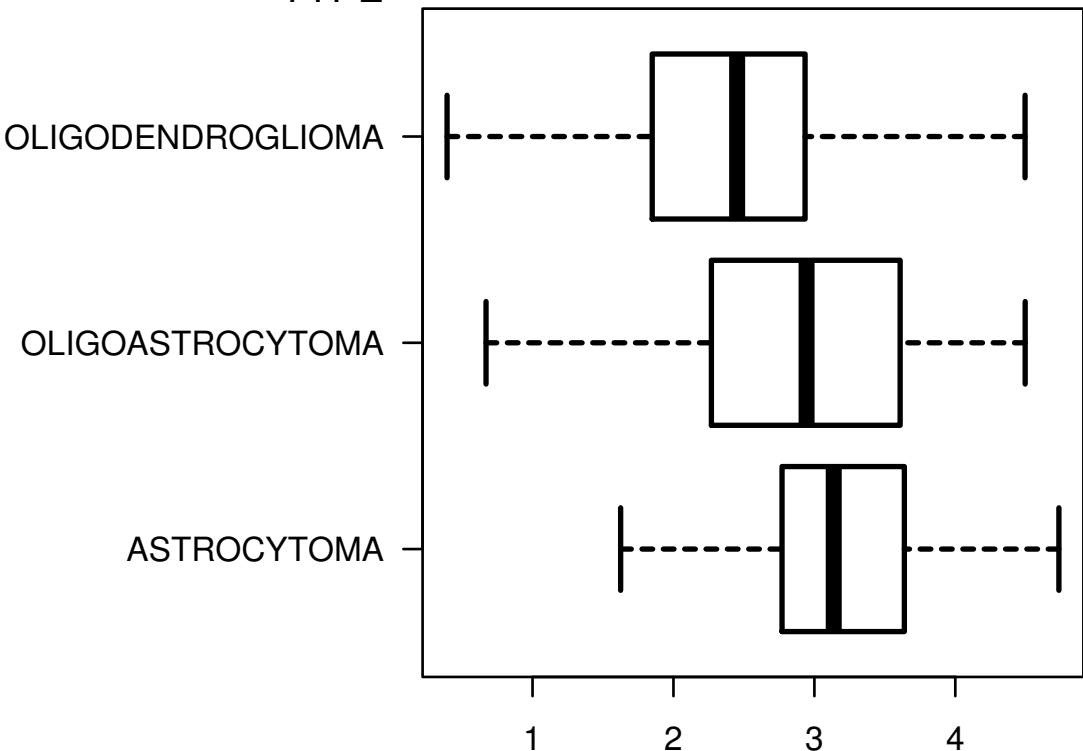


HSA-MIR-3074

HISTOLOGICAL
TYPE



Kruskal-Wallis P = 3.45e-13