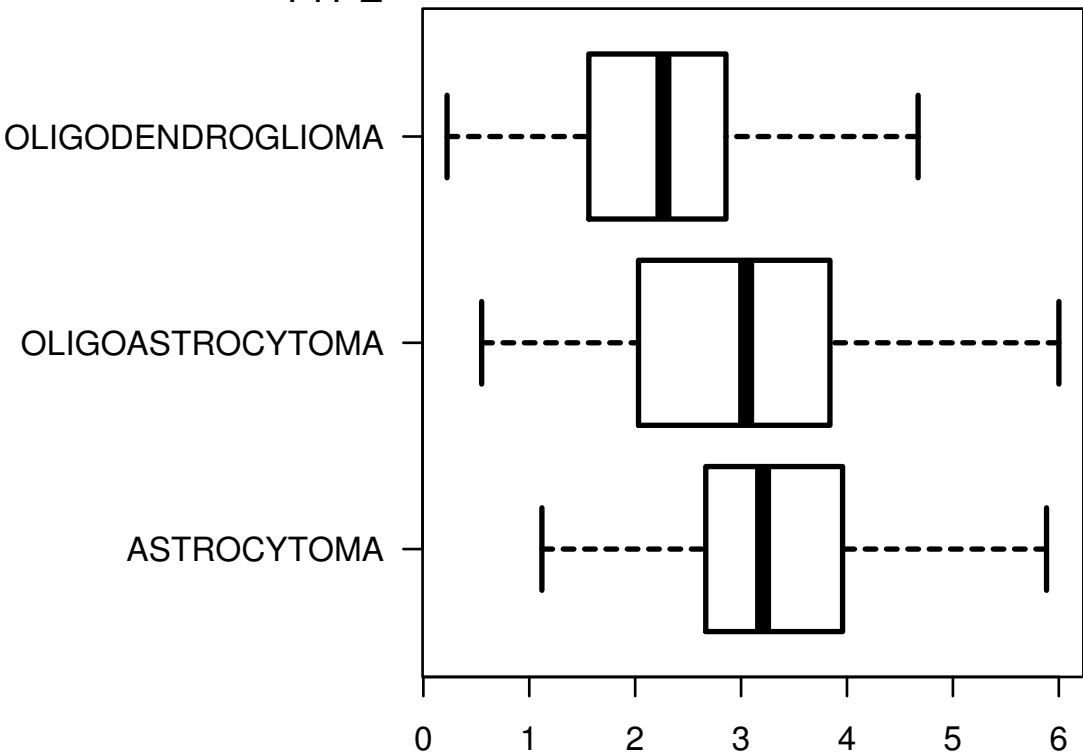


# HSA-MIR-219-1

HISTOLOGICAL  
TYPE



log<sub>2</sub>-EXPR  
Kruskal-Wallis P = 1.35e-15