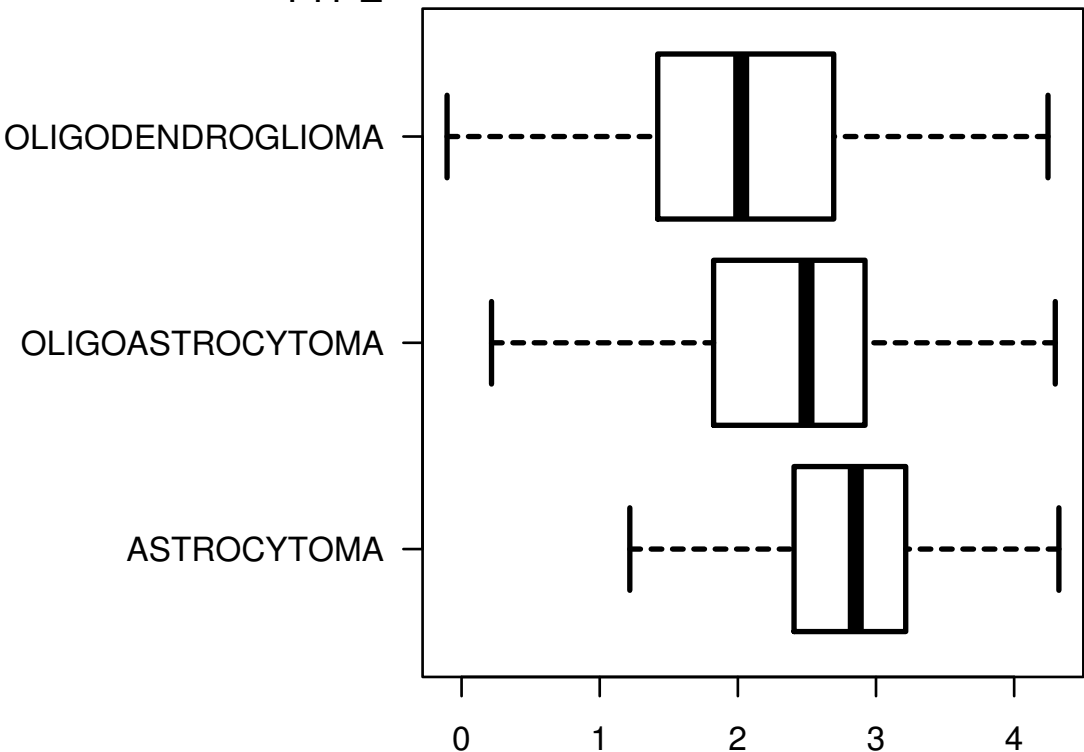


HSA-MIR-576

HISTOLOGICAL
TYPE



log₂-EXPR
Kruskal-Wallis P = 6.81e-15