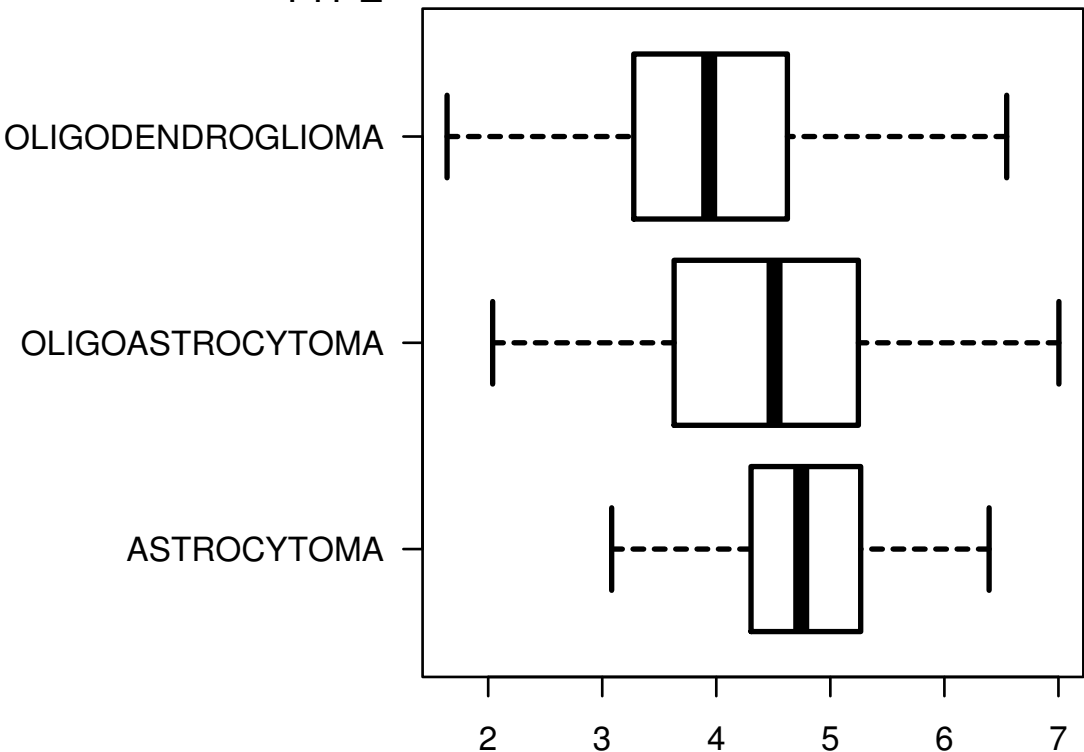


HSA-MIR-301A

HISTOLOGICAL
TYPE



log₂-EXPR
Kruskal-Wallis P = 1.69e-12