

# HSA-MIR-200B

HISTOLOGICAL

TYPE

MUCINOUS

(COLLOID)

LUNG (SOLID)

CARCINOMA

PREDOMINANT

RING

ADENOCARCINOMA

ADENOCARCINOMA

ADENOCARCINOMA

ADENOCARCINOMA

ADENOCARCINOMA

ADENOCARCINOMA

ADENOCARCINOMA

ADENOCARCINOMA

ADENOCARCINOMA

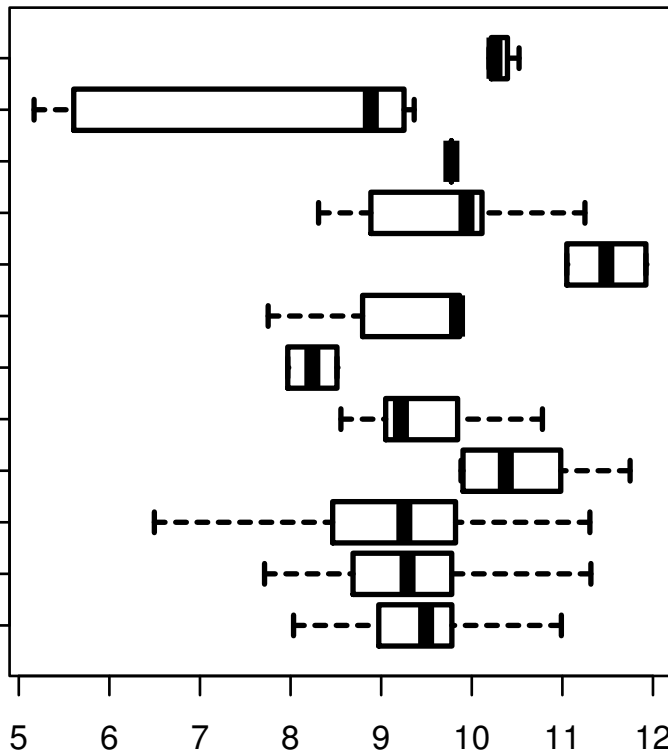
ADENOCARCINOMA

ADENOCARCINOMA

ADENOCARCINOMA

ADENOCARCINOMA

ADENOCARCINOMA



log2-EXPR

Kruskal-Wallis P = 0.000549