

MECOM|2122

HISTOLOGICAL
TYPE

MUCINOUS

LUNG (SOLID)

CARCINOMA

PREDOMINANT

RING

ADENOCARCINOMA

ADENOCARCINOMA

ADENOCARCINOMA

ADENOCARCINOMA

MICROPAPILLARY

ADENOCARCINOMA

ADENOCARCINOMA

ADENOCARCINOMA

ADENOCARCINOMA

ADENOCARCINOMA

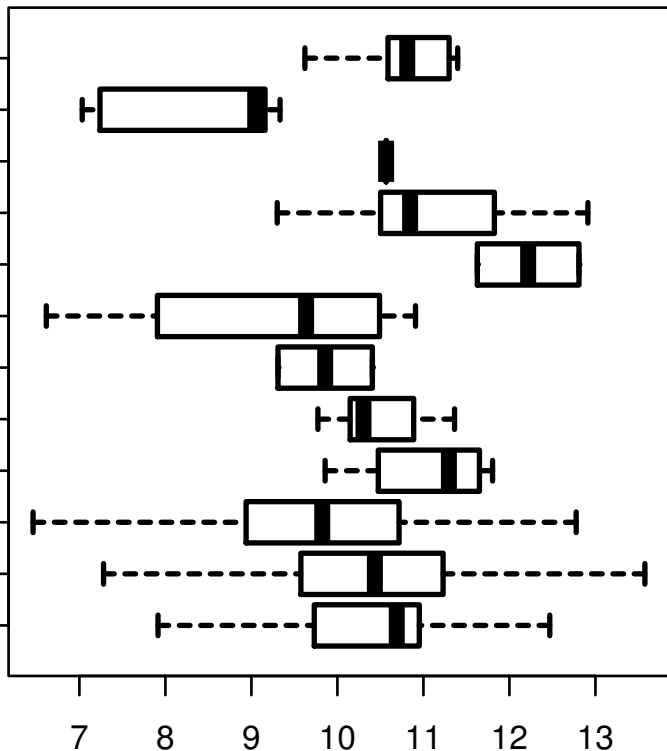
ADENOCARCINOMA

ADENOCARCINOMA

ADENOCARCINOMA

ADENOCARCINOMA

ADENOCARCINOMA



log2-EXPR

Kruskal-Wallis P = 7.88e-07