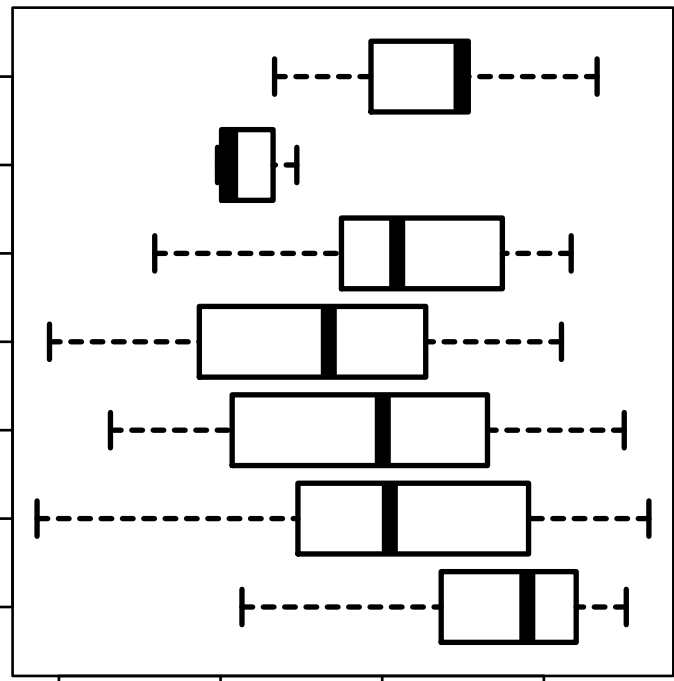


# FILIP1L

HISTOLOGICAL TYPE  
 STOMACH  
 ADENOCARCINOMA  
 STOMACH  
 SIGNET RING  
 INTESTINAL  
 ADENOCARCINOMA  
 STOMACH  
 PAPILLARY  
 INTESTINAL  
 ADENOCARCINOMA  
 STOMACH  
 ...MUCOUS  
 INTESTINAL  
 STOMACH  
 ADENOCARCINOMA  
 INTESTINAL  
 ADENOCARCINOMA  
 TUBULAR TYPE  
 STOMACH  
 NOT OTHERWISE  
 ADENOCARCINOMA  
 SPECIFIED  
 (NOS)  
 STOMACH  
 ADENOCARCINOMA  
 (NOS)  
 DIFFUSE TYPE



log2-EXPR  
 Kruskal-Wallis P = 1.23e-09