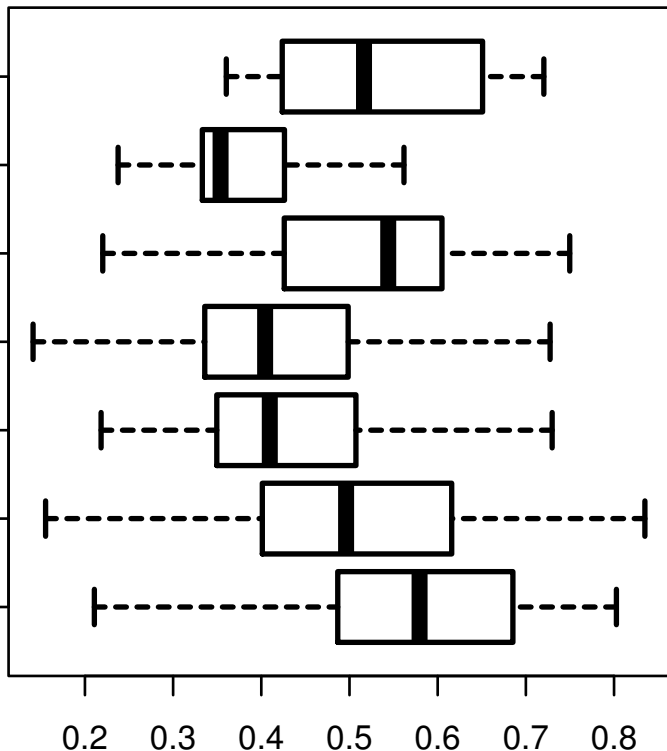


SLC23A1

HISTOLOGICAL
TYPE
STOMACH
ADENOCARCINOMA
SIGNET RING
INTESTINAL
ADENOCARCINOMA
STOMACH
RAPIDLY
INTESTINAL
ADENOCARCINOMA
TYPE
...MUCOUS
INTESTINAL
STOMACH
ADENOCARCINOMA
INTESTINAL
ADENOCARCINOMA
TUBULAR TYPE
STOMACH
NOT OTHERWISE
ADENOCARCINOMA
SPECIFIED
NOT OTHERWISE
(NOS)
STOMACH
ADENOCARCINOMA
(NOS)
DIFFUSE TYPE



log2-EXPR
Kruskal-Wallis P = 9.35e-09