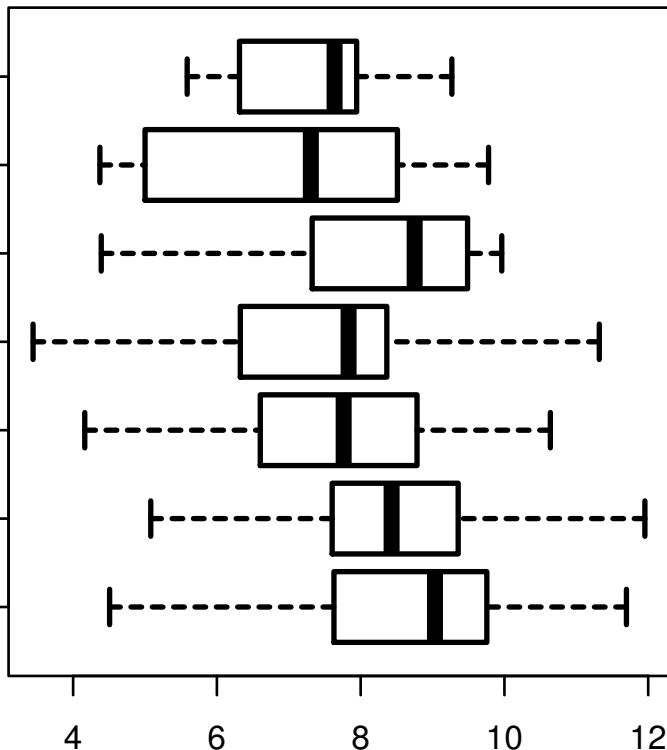


# HSA-MIR-99A

HISTOLOGICAL  
TYPE  
STOMACH  
ADENOCARCINOMA  
SIGNET RING  
INTESTINAL  
ADENOCARCINOMA  
STOMACH  
RAPIDLY  
INTESTINAL  
ADENOCARCINOMA  
STOMACH  
...MUCOUS  
INTESTINAL  
ADENOCARCINOMA  
INTESTINAL  
ADENOCARCINOMA  
TUBULAR TYPE  
STOMACH  
NOT OTHERWISE  
ADENOCARCINOMA  
SPECIFIED  
NOT OTHERWISE  
(NOS)  
STOMACH  
ADENOCARCINOMA  
(NOS)  
DIFFUSE TYPE



log2-EXPR  
Kruskal-Wallis P = 6.16e-07