

PON2

HISTOLOGICAL

TYPE

THYROID

PAPILLARY

CARCINOMA -

TALL CELL (>=

50% TALL CELL

PAPILLARY

FEATURES)

FOLLICULAR

(>= 99%

FOLLICULAR

THYROID

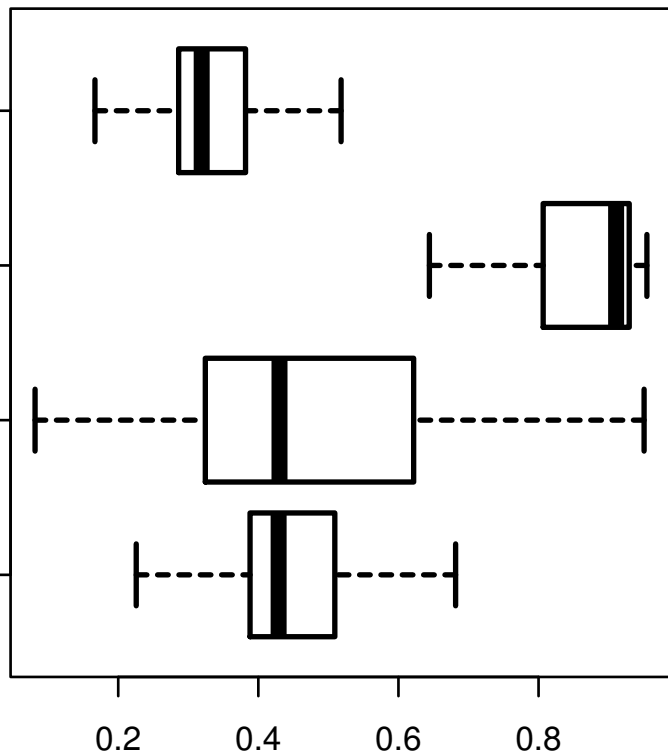
PAPILLARY

CARCINOMA -

CLASSICAL/USUAL

OTHER

SPECIFY



log2-EXPR

Kruskal-Wallis P = 8.99e-30