

HSA-MIR-30E

HISTOLOGICAL

TYPE

THYROID

PAPILLARY

CARCINOMA -

TALL CELL (>=

50% TALL CELL

PAPILLARY

FEATURES)

CARCINOMA -

FOLLICULAR

(>= 99%

FOLLICULAR

THYROID

PATTERNED)

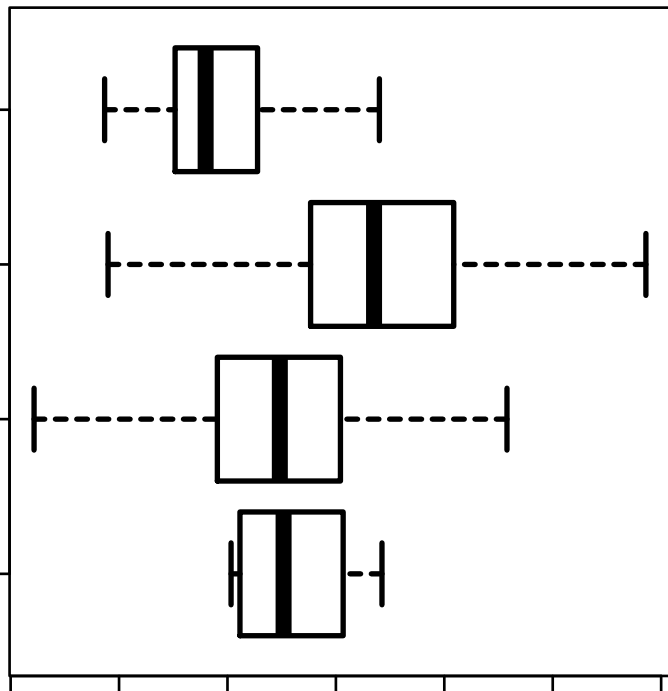
PAPILLARY

CARCINOMA -

CLASSICAL/USUAL

OTHER

SPECIFY



13.0 13.5 14.0 14.5 15.0 15.5 16.0

log2-EXPR

Kruskal-Wallis P = 5.27e-19