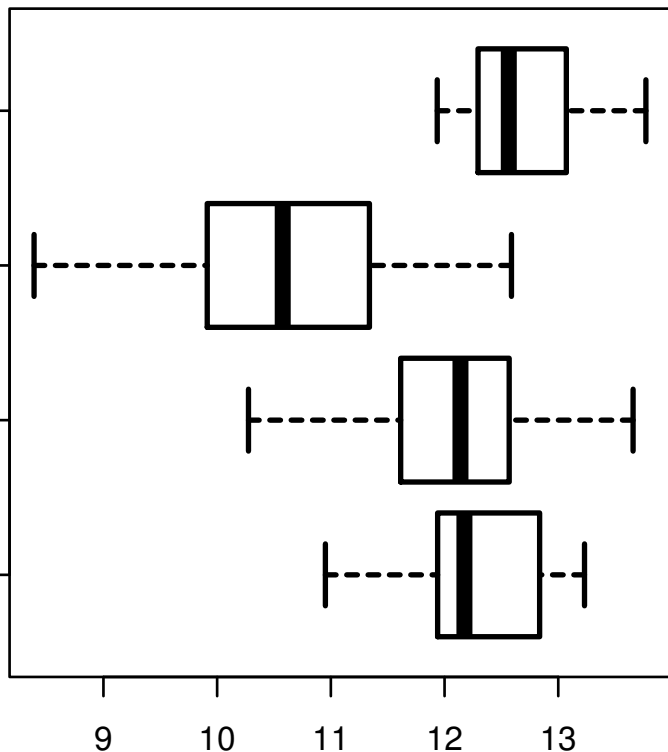


ANXA2P2|304

HISTOLOGICAL
TYPE
THYROID
PAPILLARY
CARCINOMA -
TALL CELL (>=
50% TALL CELL
PAPILLARY
FEATURES)
CARCINOMA -
FOLLICULAR
(>= 99%
FOLLICULAR
THYROID
PATTERNED)
PAPILLARY
CARCINOMA -
CLASSICAL/USUAL
OTHER
SPECIFY



log2-EXPR
Kruskal-Wallis P = 2.86e-32