

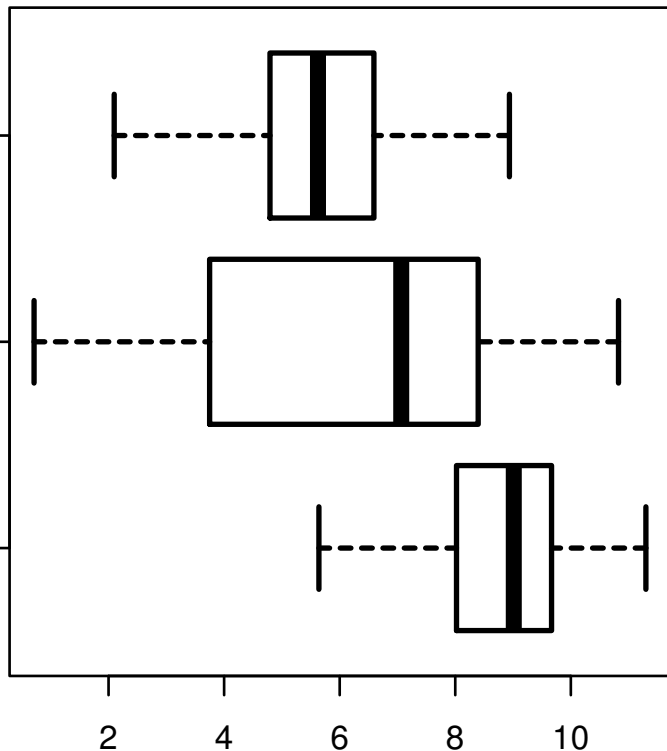
IL20RA|53832

HISTOLOGICAL
TYPE

SEROUS
ENDOMETRIAL
ADENOCARCINOMA

MIXED SEROUS
AND
ENDOMETRIOID

ENDOMETRIOID
ENDOMETRIAL
ADENOCARCINOMA



log₂-EXPR
Kruskal-Wallis P = 8.33e-37