

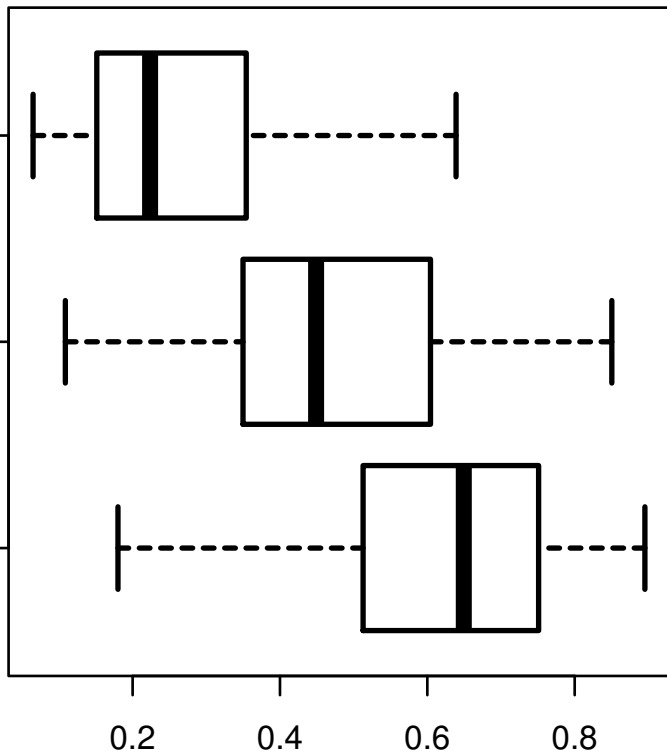
ADAMTS16

HISTOLOGICAL
TYPE

SEROUS
ENDOMETRIAL
ADENOCARCINOMA

MIXED SEROUS
AND
ENDOMETRIOID

ENDOMETRIOID
ENDOMETRIAL
ADENOCARCINOMA



log2-EXPR
Kruskal-Wallis P = 1.5e-29