

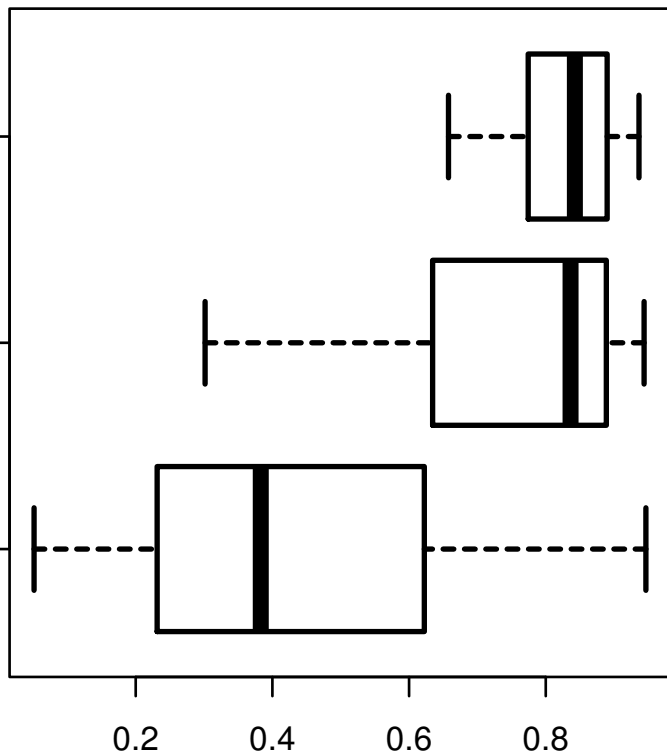
# RASGRF1

HISTOLOGICAL  
TYPE

SEROUS  
ENDOMETRIAL  
ADENOCARCINOMA

MIXED SEROUS  
AND  
ENDOMETRIOID

ENDOMETRIOID  
ENDOMETRIAL  
ADENOCARCINOMA



log2-EXPR

Kruskal-Wallis P = 5.69e-32