

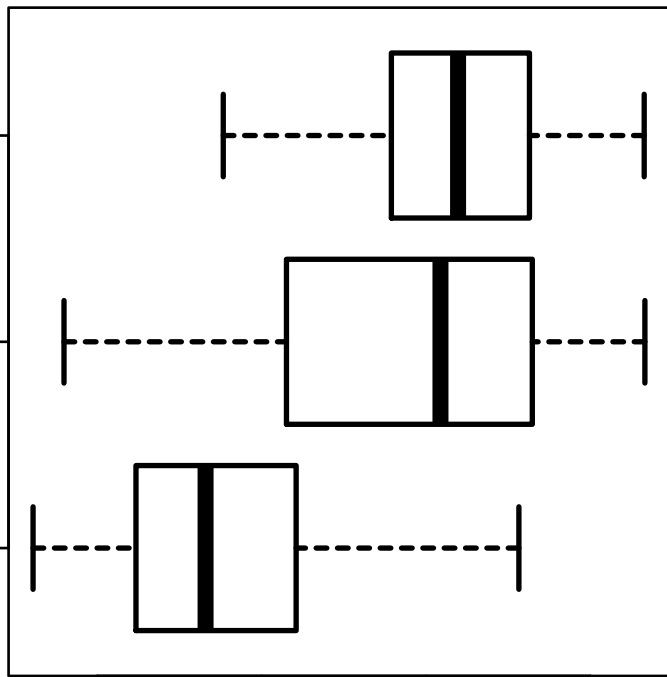
# DNAI1

HISTOLOGICAL  
TYPE

SEROUS  
ENDOMETRIAL  
ADENOCARCINOMA

MIXED SEROUS  
AND  
ENDOMETRIOID

ENDOMETRIOID  
ENDOMETRIAL  
ADENOCARCINOMA



0.2

0.4

0.6

0.8

log2-EXPR

Kruskal-Wallis P = 8.8e-30