

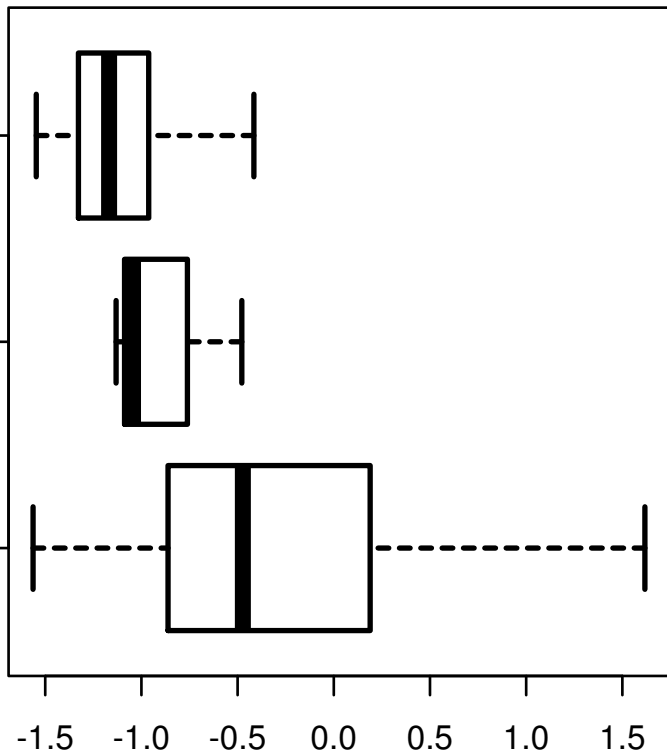
HISTOLOGICAL  
TYPE

**ESR1|ER-ALPHA\_PS118-R-V**

SEROUS  
ENDOMETRIAL  
ADENOCARCINOMA

MIXED SEROUS  
AND  
ENDOMETRIOID

ENDOMETRIOID  
ENDOMETRIAL  
ADENOCARCINOMA



log<sub>2</sub>-EXPR

Kruskal-Wallis P = 8.03e-07