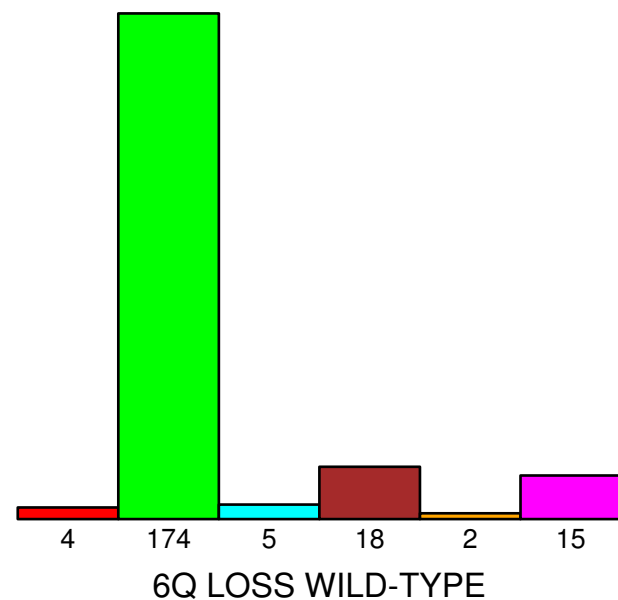
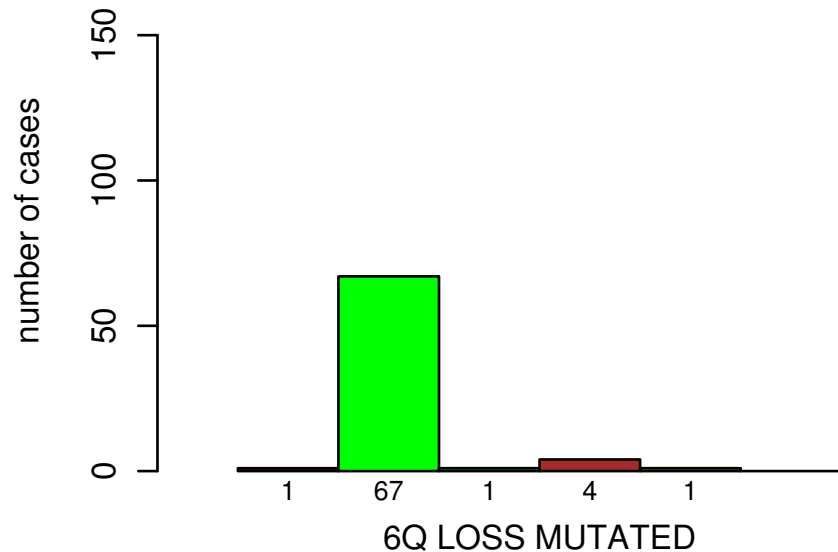


## HISTOLOGICAL\_TYPE



- ADENOSQUAMOUS
- CERVICAL SQUAMOUS CELL CARCINOMA
- ENDOCERVICAL ADENOCARCINOMA OF TH
- ENDOCERVICAL TYPE OF ADENOCARCINOMA OF EN
- ENDOMETRIOID ADENOCARCINOMA OF EN
- MUCINOUS ADENOCARCINOMA OF ENDOCI

Fisher's exact test  $P = 0.126$