

HSA-MIR-192

STOLOGICAL_TYPE

MUCINOUS

ADENOCARCINOMA

OF

ENDOCERVICAL

ENDOMETRIUM

TYPE

ADENOCARCINOMA

OF ENDOCERVIX

ENDOCERVICAL

TYPE OF

ADENOCARCINOMA

ENDOCERVICAL

ADENOCARCINOMA

OF THE USUAL

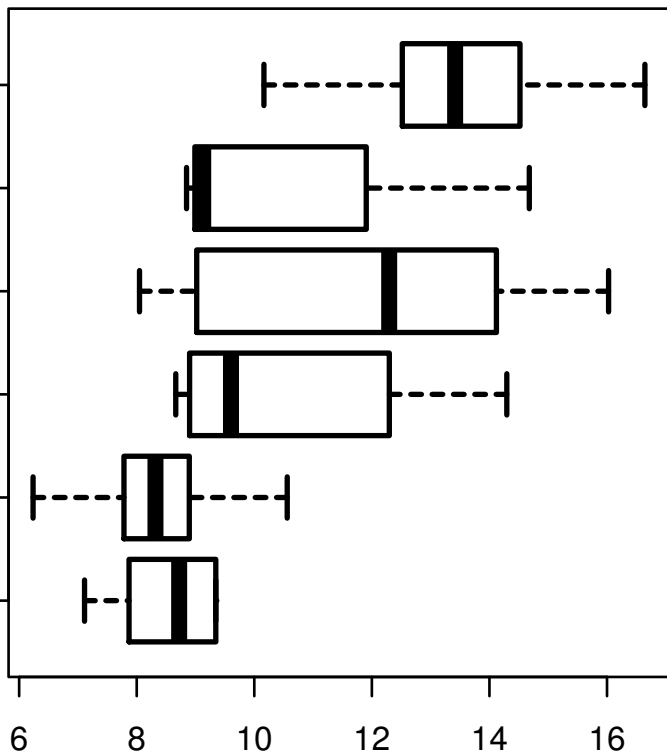
CERVICAL

TYPE

SQUAMOUS CELL

CARCINOMA

ADENOSQUAMOUS



log2-EXPR

Kruskal-Wallis P = 2.94e-13