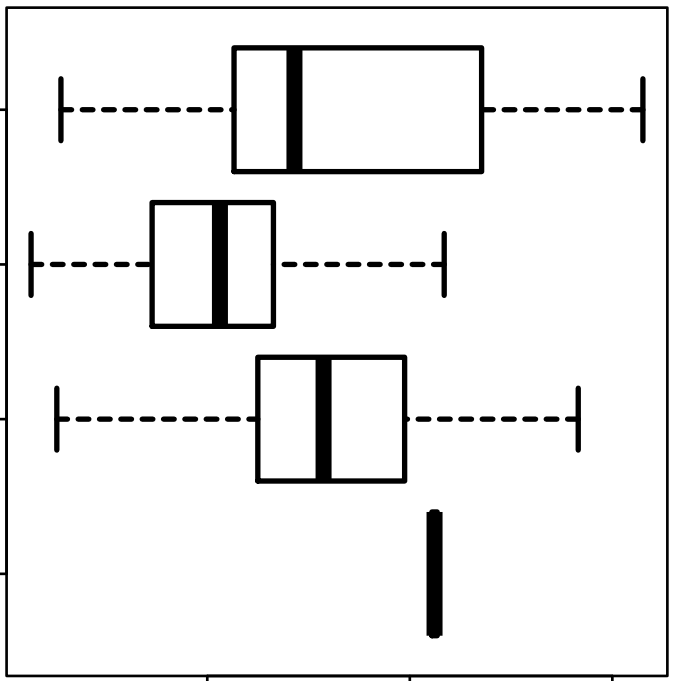


XIAP|XIAP-R-C

STOLOGICAL_TYPE

- THYROID PAPILLARY CARCINOMA - TALL CELL (>= 50% TALL CELL PAPILLARY FEATURES)
- FOLLICULAR (>= 99% FOLLICULAR PATTERNED) THYROID PAPILLARY CARCINOMA - CLASSICAL/USUAL
- OTHER SPECIFY



log2-EXPR
Kruskal-Wallis P = 2.43e-07