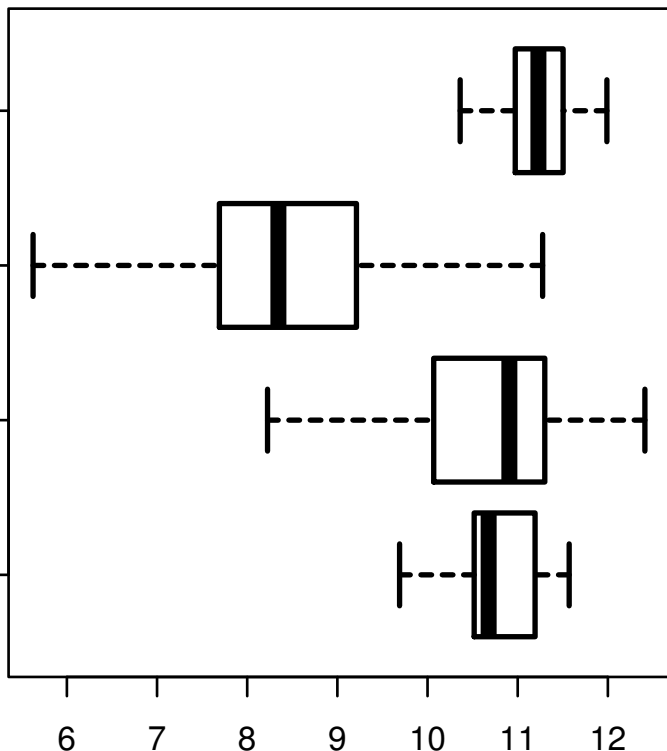


ERBB3|2065

STOLOGICAL_TYPE

THYROID
PAPILLARY
CARCINOMA -
TALL CELL (>=
50% TALL CELL
PAPILLARY
FEATURES)
CARCINOMA -
FOLLICULAR
(>= 99%
FOLLICULAR
PATTERNED)
THYROID
PAPILLARY
CARCINOMA -
CLASSICAL/USUAL

OTHER
SPECIFY



log2-EXPR
Kruskal-Wallis P = 3.5e-32