

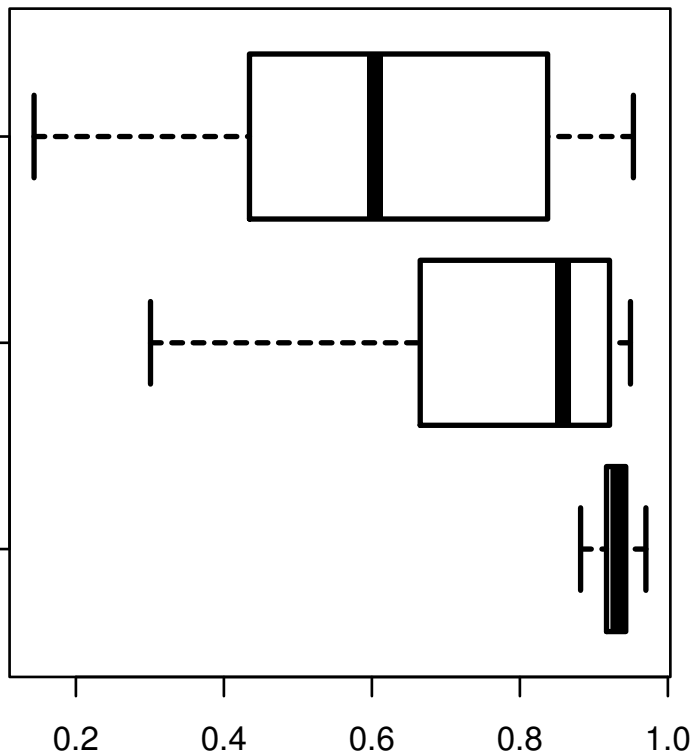
# PPIH

STOLOGICAL\_TYPE

SEROUS  
ENDOMETRIAL  
ADENOCARCINOMA

MIXED SEROUS  
AND  
ENDOMETRIOID

ENDOMETRIOID  
ENDOMETRIAL  
ADENOCARCINOMA



log<sub>2</sub>-EXPR

Kruskal-Wallis P = 3.02e-32