

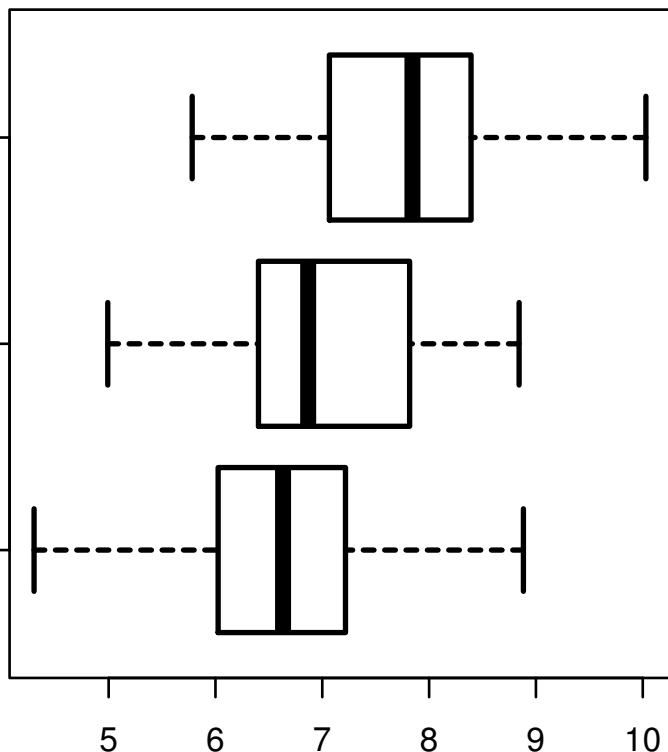
# HSA-MIR-221

STOLOGICAL\_TYPE

SEROUS  
ENDOMETRIAL  
ADENOCARCINOMA

MIXED SEROUS  
AND  
ENDOMETRIOID

ENDOMETRIOID  
ENDOMETRIAL  
ADENOCARCINOMA



Kruskal-Wallis P = 2.8e-21