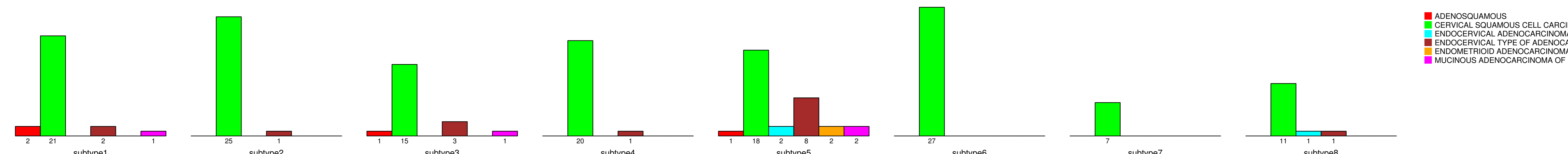


# HISTOLOGICAL\_TYPE

number of cases



- ADENOSQUAMOUS
- CERVICAL SQUAMOUS CELL CARCINOMA
- ENDOCERVICAL ADENOCARCINOMA OF THE USUAL T
- ENDOCERVICAL TYPE OF ADENOCARCINOMA
- ENDOMETRIOID ADENOCARCINOMA OF ENDOCERVIX
- MUCINOUS ADENOCARCINOMA OF ENDOCERVICAL T

Fisher's exact test P = 0.0331