

# MAP2K1|MEK1

STOLOGICAL\_TYPE

MUCINOUS

ADENOCARCINOMA

OF

ENDOCERVICAL

ENDOMETRIUM

TYPE

ADENOCARCINOMA

OF ENDOCERVIX

ENDOCERVICAL

TYPE OF

ADENOCARCINOMA

ADENOCARCINOMA

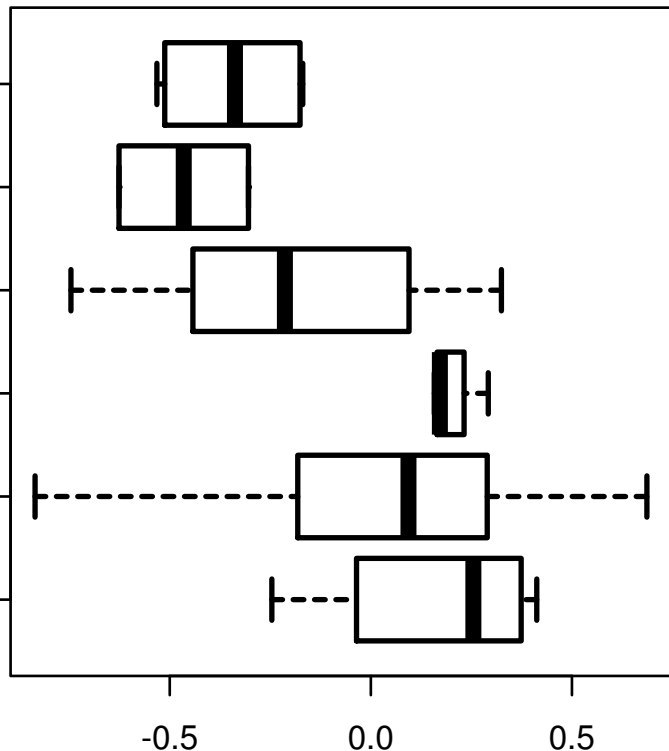
OF THE USUAL

CERVICAL

SQUAMOUS CELL

CARCINOMA

ADENOSQUAMOUS



log2-EXPR

Kruskal-Wallis P = 0.00368