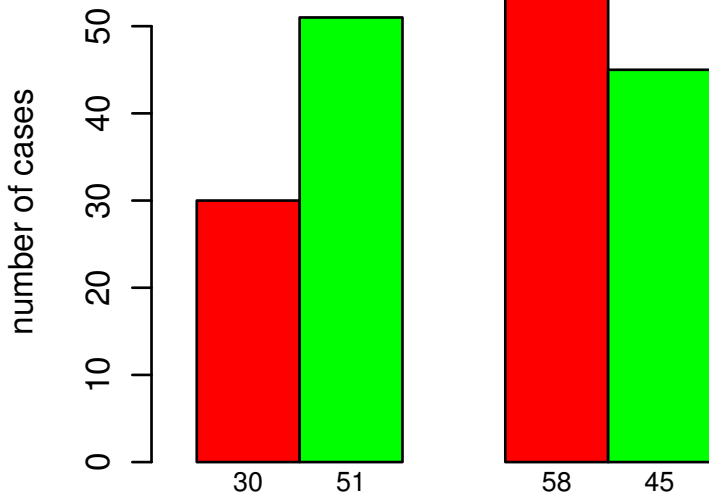


HISTOLOGICAL_TYPE

ESOPHAGUS ADENOCARCINOMA |
ESOPHAGUS SQUAMOUS CELL CA



DEL PEAK 29(11Q25) MUTATED

Fisher's exact test P = 0.0115