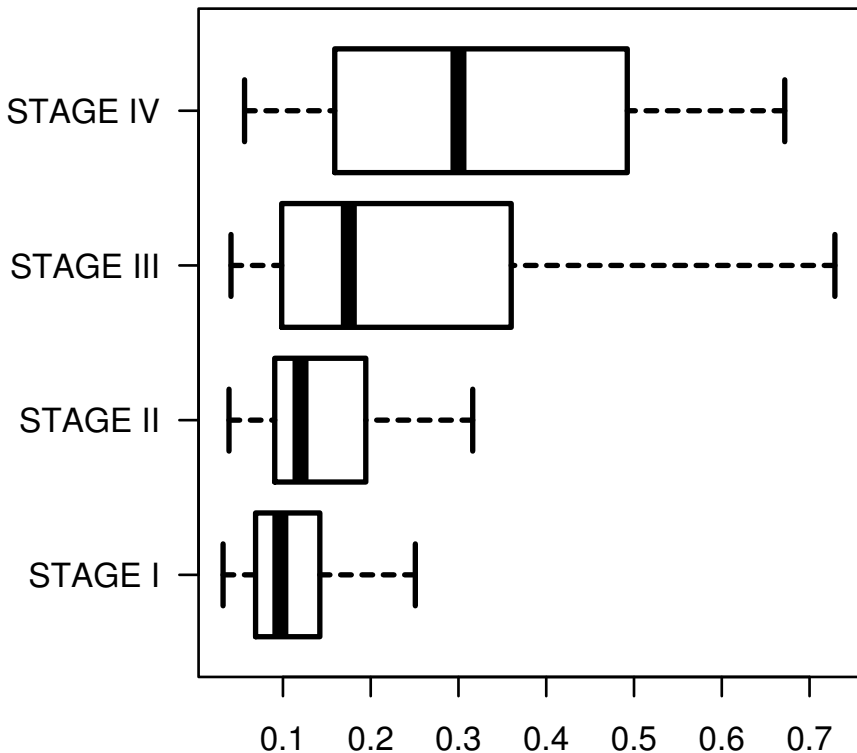


PATHOLOGIC_STAGE

SOX8



log2-EXPR
Kruskal-Wallis P = 7.55e-25