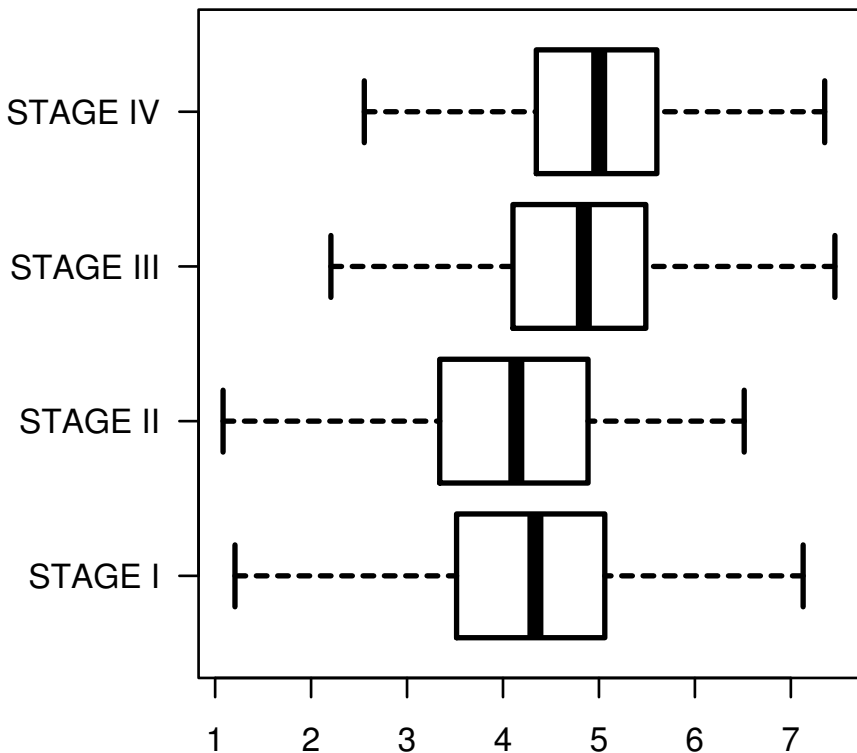


PATHOLOGIC_STAGE

HSA-MIR-365-2



log₂-EXPR
Kruskal-Wallis P = 1.58e-12