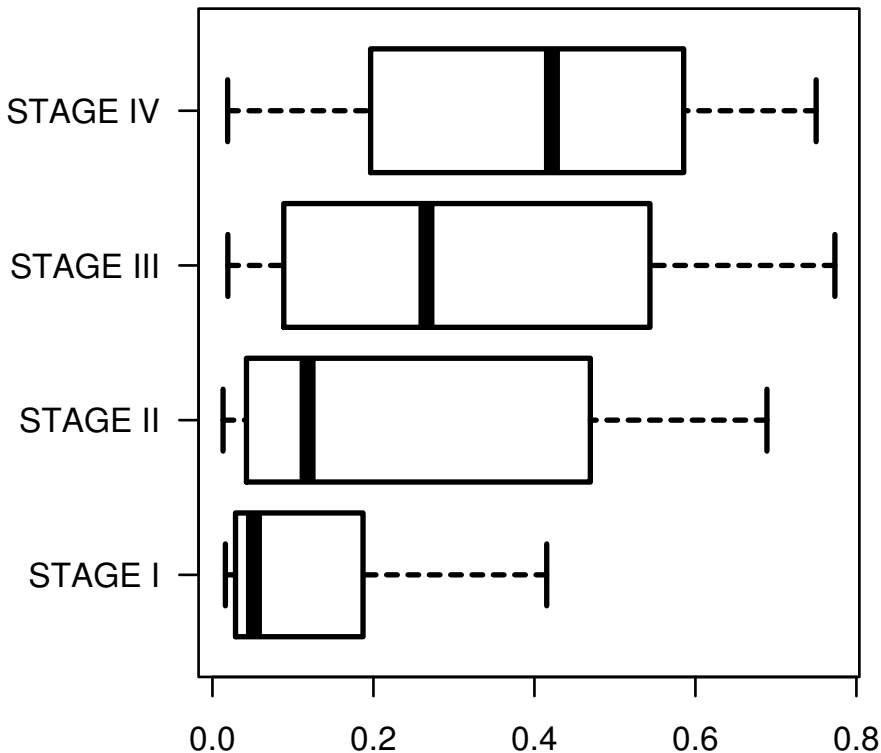


PATHOLOGIC\_STAGE

# SOX8



Kruskal-Wallis P = 2.18e-15