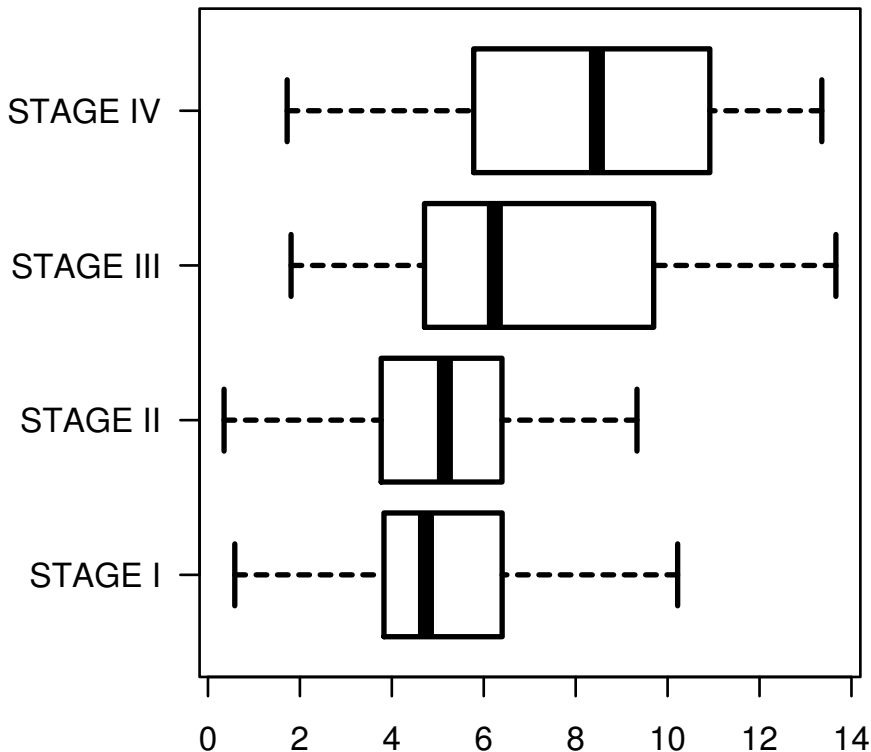


PATHOLOGIC_STAGE

IL20RB|53833



log₂-EXPR
Kruskal-Wallis P = 1.62e-16