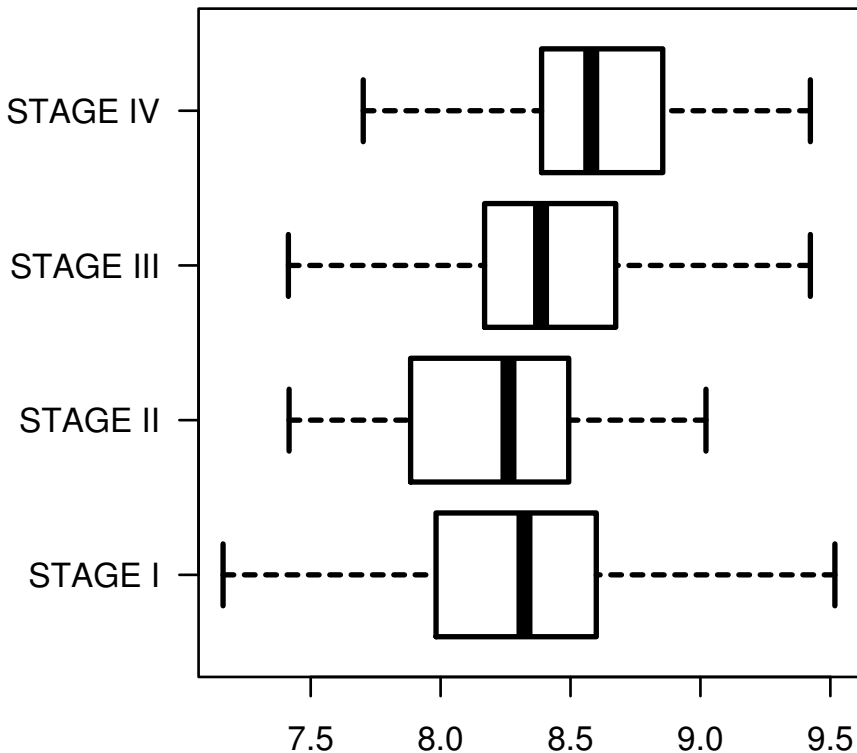


PATHOLOGIC_STAGE

HSA-MIR-106B



log2-EXPR
Kruskal-Wallis P = 1.72e-07