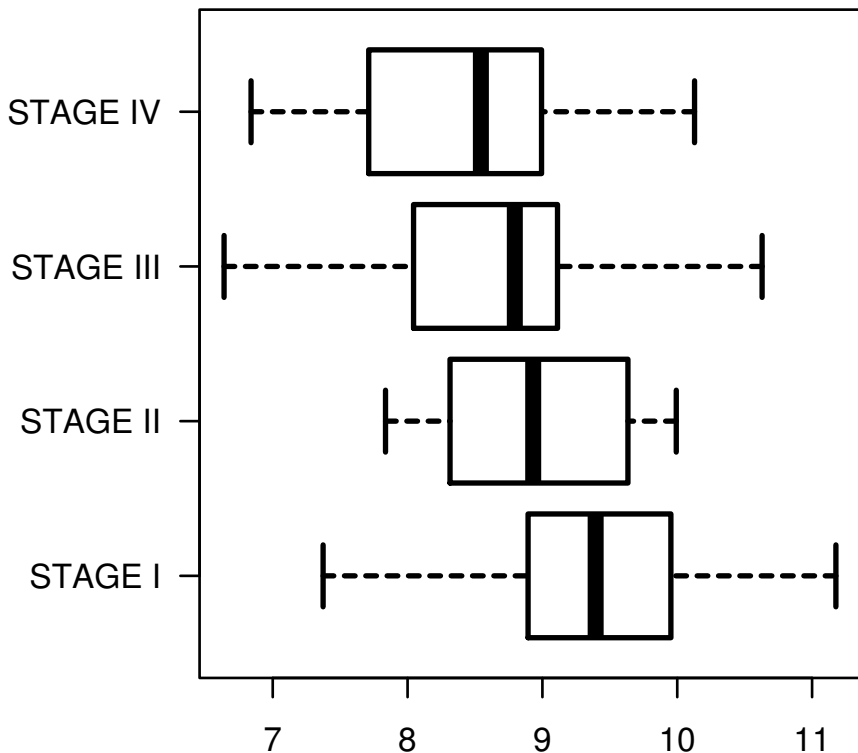


HSA-MIR-200B

PATHOLOGIC_STAGE



log₂-EXPR
Kruskal-Wallis P = 8.45e-09