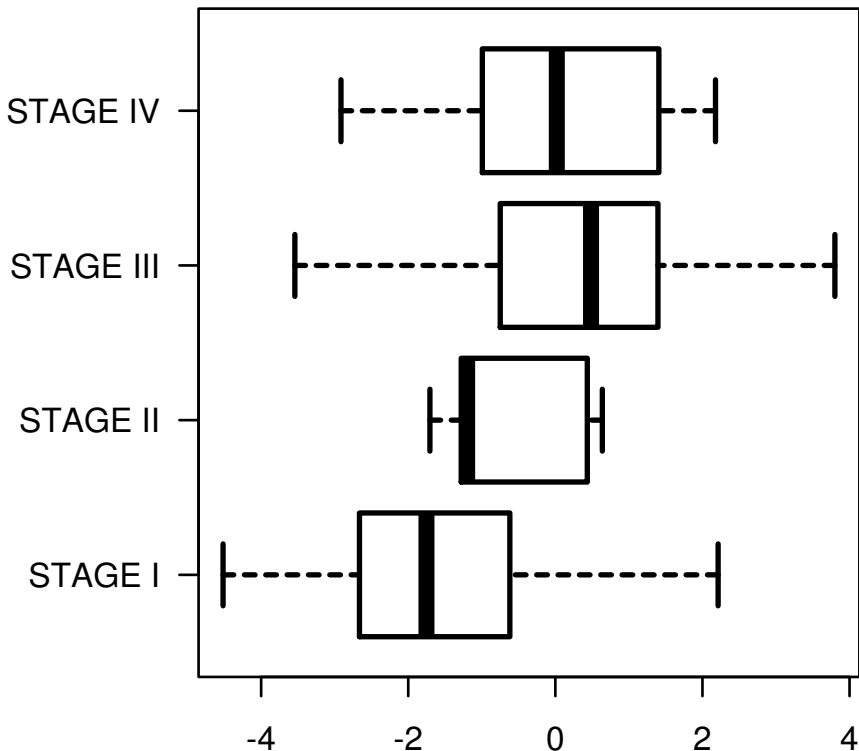


PATHOLOGIC_STAGE

HSA-MIR-216A



log2-EXPR
Kruskal-Wallis P = 2.86e-06