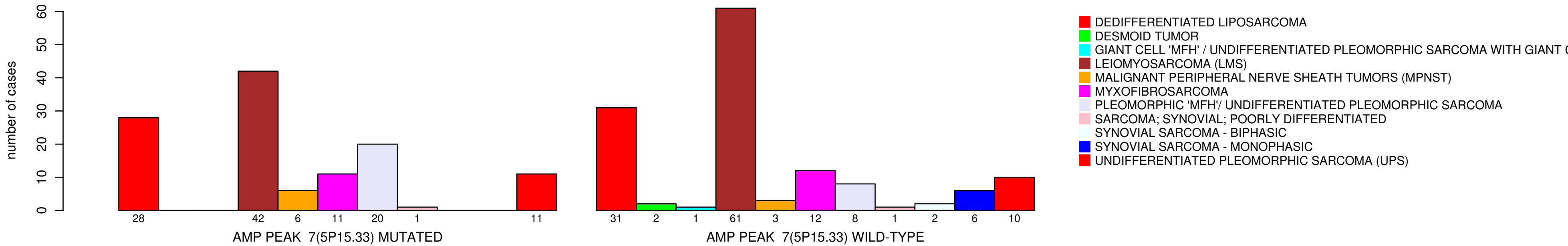


HISTOLOGICAL_TYPE



- DEDIFFERENTIATED LIPOSARCOMA
- DESMOID TUMOR
- GIANT CELL 'MFH' / UNDIFFERENTIATED PLEOMORPHIC SARCOMA WITH GIANT C
- LEIOMYOSARCOMA (LMS)
- MALIGNANT PERIPHERAL NERVE SHEATH TUMORS (MPNST)
- MYXOFIBROSARCOMA
- PLEOMORPHIC 'MFH'/ UNDIFFERENTIATED PLEOMORPHIC SARCOMA
- SARCOMA; SYNOVIAL; POORLY DIFFERENTIATED
- SYNOVIAL SARCOMA - BIPHASIC
- SYNOVIAL SARCOMA - MONOPHASIC
- UNDIFFERENTIATED PLEOMORPHIC SARCOMA (UPS)