

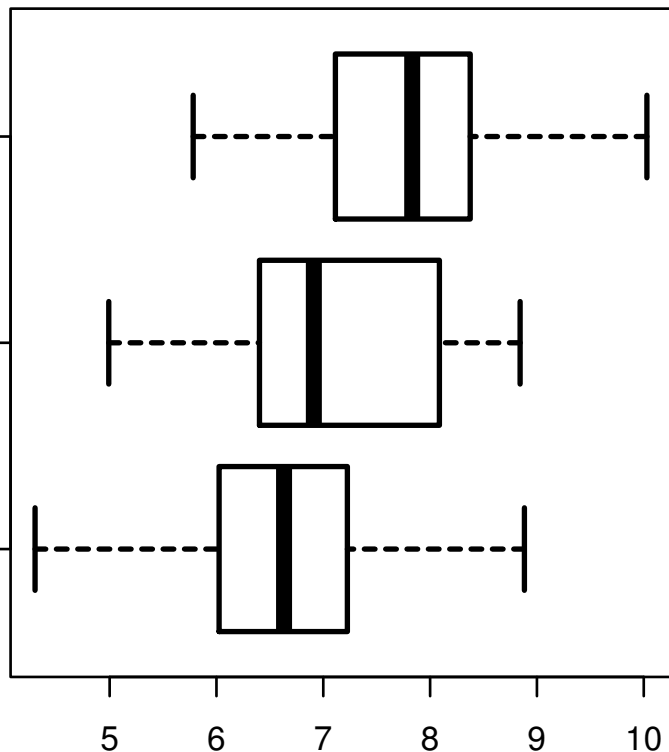
HSA-MIR-221

STOLOGICAL_TYPE

SEROUS
ENDOMETRIAL
ADENOCARCINOMA

MIXED SEROUS
AND
ENDOMETRIOID

ENDOMETRIOID
ENDOMETRIAL
ADENOCARCINOMA



Kruskal-Wallis P = 2.14e-21